

Vascular Complications After Renal Transplantation

Taylan Ozgur Sezer and Cuneyt Hoscoskun
*Department of General Surgery and Transplantation Unit,
Ege University School of Medicine, Izmir,
Turkey*

1. Introduction

Renal transplantation has become the treatment of choice for end-stage renal disease due to advances in surgical techniques, perioperative management, and immunosuppressive regimens. Surgical techniques for kidney transplantation were first described in 1951 by Kuss et al. and have since changed very little. The most common surgical procedure is extraperitoneal transplantation in the right iliac fossa, with end-to-side to the external iliac artery or end-to-end anastomosis to the internal iliac artery, and end-to-side anastomosis to the external iliac vein.

The overall incidence of vascular complications following kidney transplantation is low, especially when compared to other solid organ transplantation of such organs as the liver or pancreas. The incidence of vascular complications following renal transplantation ranges from 3% to 15%.¹ Arterial complications occur more frequently and are more dangerous than venous. Both arterial and venous thromboses tend to occur within the first few days of transplantation. Improvements in immunosuppressive therapy have led to a 1-year post transplantation acute rejection incidence rate of <20%. The incidence of graft loss due to acute and chronic rejection is decreasing; however, the incidence of early allograft loss due to acute vascular complications has remained constant, accounting for a proportionally higher percentage of early loss. Reducing the incidence of vascular complications depends to a great extent on the careful evaluation of the recipient, the donor kidney, and the surgical technique used for implantation.

1.1 Transplantation region

As a general rule, left kidney is implanted in the right iliac fossa, whereas right kidney is implanted in the left iliac fossa. Using this technique the urinary collecting system is medially located, facilitating easy access to the ureter and possible percutaneous kidney biopsy; however, because left donor nephrectomy is commonly performed and the right iliac veins are more superficial, kidneys are implanted in the right retroperitoneal iliac fossa. The left iliac fossa is reserved primarily for pancreas transplantation candidates, patients with previous transplants, and those with vascular problems. In patients undergoing

simultaneous pancreas and renal transplantation, or in those with a history of surgery in both iliac regions intraperitoneal transplantation should be performed.

1.2 Which kidney to choose – left or right?

Right and left kidney transplant outcomes are similar;² however, given a choice surgeons prefer the left kidney because the left renal vein is longer and less fragile, and anastomosis to the recipient right external iliac vein, which is situated superficial, is easier. Right kidney transplantation leads to more stretching of the anastomosis site because the right renal vein is short. On the other hand, a long renal artery may lead to a kink. In transplantation of kidneys with multiple renal arteries the contralateral kidney should be used because the duration of surgery is long, and hot and cold ischemia negatively affect graft survival.

1.3 Preparation of the allograft

Donor kidneys should be prepared on the back table before implantation in the recipient, whether obtained from a deceased or a living donor. Arterial anomalies, atheromatous plaques, thromboses, and intimal flaps that may be overlooked during explantation or donor nephrectomy. In such cases the duration of hot or cold ischemia will be kept to a minimum due to preparation performed on the back table.

In living donor transplantation accessory superior pole or inferior pole arteries that may have escaped detection during back table preparation may become evident with cold perfusion; however, in transplants performed with deceased organs prepared with in situ perfusion, accessory arteries may be overlooked. The tissue surrounding the donor renal artery and vein should be mobilized without extreme dissection. Hemostasis should be maintained using cauterization to separate the perirenal fat tissue and tying or clipping the small venous structures, which will decrease the volume of bleeding during reperfusion.

In deceased kidney transplantation the second flushing at the back table after explantation helps clean away remnant venous blood and facilitates detection of veins that may have been previously overlooked. Furthermore, flushing kidneys twice reduced the primary non-function rate.³ In donors with multiple arteries, 2 arteries should be unified as a single artery via trouser-like stenting, if possible (artery diameter >3 mm), and used as a single anastomosis in the recipient (Figure 1a). The smaller graft artery can be anastomosed end-to-side to the larger one (Figure 1b). Alternately, there can be 2 separate anastomoses performed on the internal iliac and external iliac arteries (Figure 1c).

Superior pole arteries with a diameter <1 mm and an ischemic surface <1 cm² can be ligated. Even if the surface appears pink with reperfusion following superior pole artery ligation, there will be a small ischemic area in deep region due to the nature of the renal artery system. As the inferior pole artery might also nourish the ureter, it is more difficult to sacrifice, and because of the area it nourishes there is the potential for ureterovesical anastomosis leakage, ureteral necrosis, and urinary fistula. The inferior pole artery should be anastomosed end-to-side to the renal artery, and in cases in which the iliac artery is extremely atherosclerotic it should be anastomosed to the inferior epigastric artery in an end-to-end fashion.

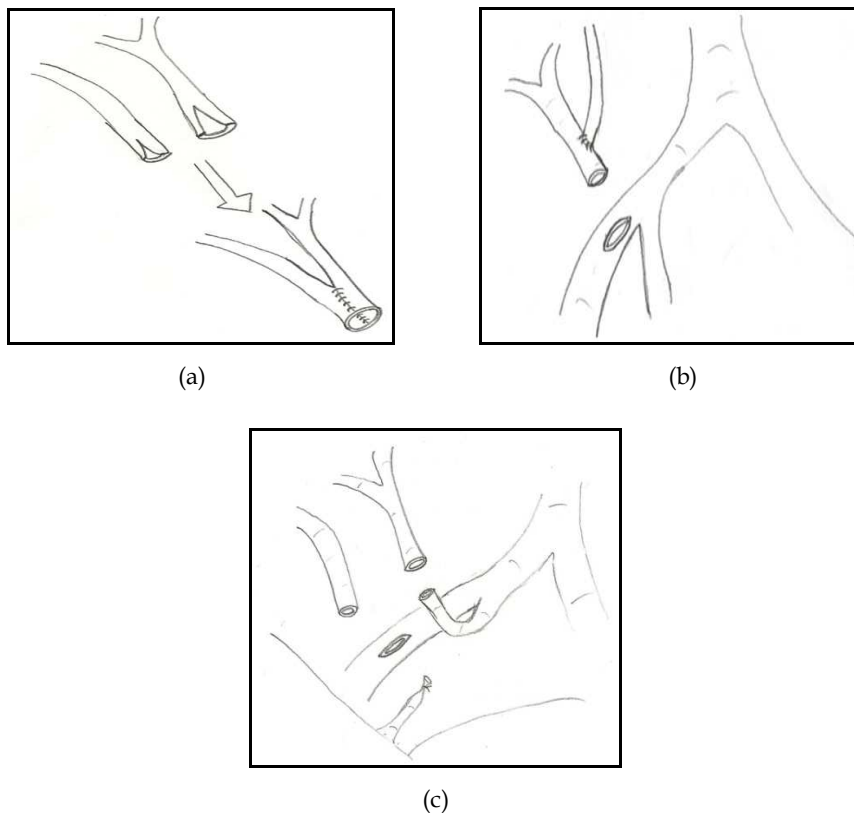


Fig. 1. There are multiple alternatives in artery anastomosis. **a.** Anastomosis of donor renal arteries before transplantation. **b.** Donor accessory renal artery can be anastomosed to main renal artery. **c.** Two renal arteries can be anastomosed to the internal iliac artery and external iliac artery.

1.4 Venous anastomosis

In living donor transplantation if the donor does not have multiple renal arteries or collecting system anomalies the left kidney should be used, because the left renal vein is longer. In deceased renal transplantation choice of side is unimportant. The left kidney is preferred primarily because the right renal vein is shorter and the right renal vein wall is thinner than the left. Vein anastomosis should be performed prior to artery anastomosis. The most common technique is end-to-side anastomosis between the renal vein and external iliac vein (Figure 2); when this cannot be performed other techniques can be used. If the renal vein is short the internal iliac vein can be ligated to achieve mobility, followed by end-to-side anastomosis to the external iliac vein. When the branches of the external iliac vein are occluded and the vena cava is functional, end-to-side anastomosis to the vena cava can be performed. When there is a short renal vein in cadaver transplants, venoplasty can be performed to extend the renal vein that is explanted along with vena cava.

After the iliac vein's anastomosis site is determined a venous clamp is situated horizontally and venotomy is performed. To prevent stitching from the opposite wall 5/0 stitches are placed in all 4 quadrants of the iliac vein. It is stitched continuously with 5/0 non-absorbable material. Another technique is situation of venous clamp horizontally. Venotomy is performed in accordance with the diameter of renal vein that will be anastomosed. Following the posterior wall, anterior wall anastomoses is performed with continue suture technique. In this technique, from outside to inside at distal corner of iliac venotomy and from inside to outside at distal corner of renal vein, following posterior wall, anterior wall is erected continuously with the 6 / 0 polypropylene suture material. Surgeons must closely monitor the tension of the anastomosis and look for kinks (Figure 2).

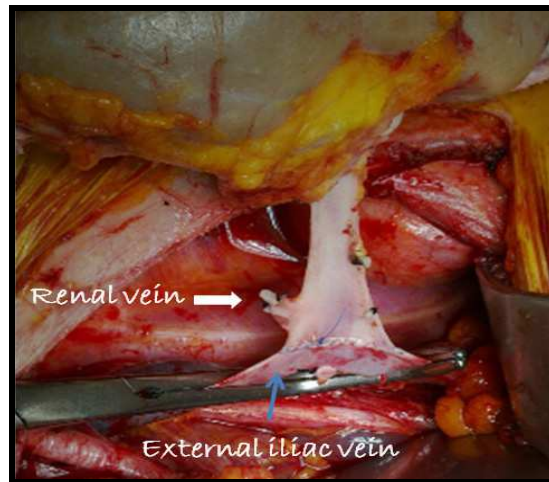


Fig. 2. End-to-side anastomosis of renal vein to the external iliac vein.

1.5 Arterial anastomosis

The renal arteries typically originate from the sides of the abdominal aorta, 1-2 cm distal of the superior mesenteric artery from the level of second lumbar vertebra. Normally, a single renal artery crosses the crura of the diaphragm and provides branches to the adrenal gland, kidneys, and ureters. Anatomical variation is more frequent than expected. Celiac truncus, superior mesenteric artery, phrenic artery, aortic bifurcation, common iliac artery, and even contralateral renal artery origin have been reported. Variations can be misleading during explantation and result in accidents during dissection. Renal arteries can be multiple (2-4 arteries) and in cadaver explantation they should always be removed from the aorta with a patch. Multiple arteries tend to be bilateral. The right renal artery is located behind the vena cava and is longer than the left (right: 0.8-8.0 cm; left: 0.5-6 cm). Renal artery diameter differs in males and females and is approximately 6.4-7.8 mm.

In 20% of cases the left kidney has multiple renal arteries.⁴ An accessory superior pole renal artery <1 mm can be fastened; however, for arteries with a diameter similar to the common renal artery anastomosis should be performed. When there a 2 renal arteries both can be anastomosed to the external iliac artery end-to-side, one can be anastomosed end-to-end to

the internal iliac artery and the other end-to-side to the external iliac artery, or the common renal artery can be anastomosed to the external iliac artery end-to-side and the inferior pole artery can be anastomosed to the inferior epigastric artery end-to-end. When the appropriate technique is used the vascular complication rate of multiple renal artery transplantation is similar to that of single renal artery transplantation.⁵

In order to decrease postoperative lymphocele lymphatic channels surrounding the artery should be fastened and dissected as little as the anastomosis area. Arterial anastomosis is commonly performed in an end-to-side to the external iliac artery; however, in the right kidney, end-to-end anastomosis to the internal iliac artery can be performed. In such cases the contralateral internal iliac artery must not be fastened. Arterial dissection should be performed with vigilance because in marginal donors there could be arterial plaques.

When dissection is completed the artery clamp should be positioned horizontally in a region without arterial plaques. Because the right kidney artery is long, it can be shortened to prevent formation of a kink. In left kidney transplantation anastomosis can be performed end-to-end to the internal iliac artery because the left renal artery is short. For large-diameter arteries anastomosis should be performed in a continuous fashion with 6/0 non-absorbable material and for small-diameter arteries it should be performed one-by-one with 7/0 non-absorbable material (Figure 3). In a similar fashion, anastomosis is performed using an aortic patch in deceased transplants.

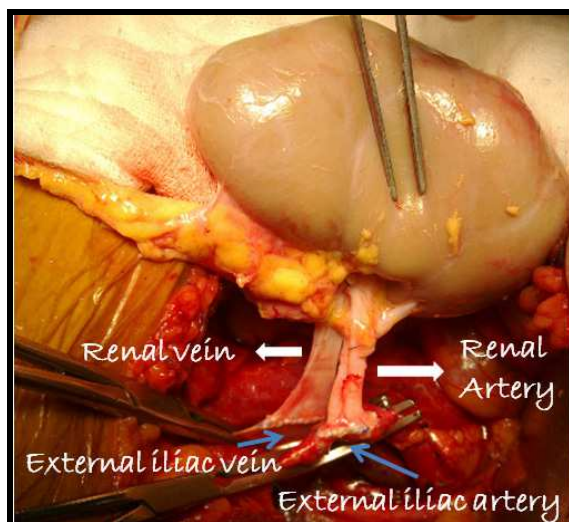
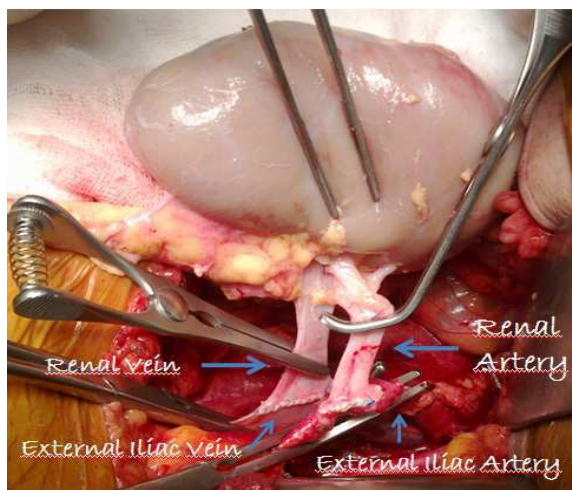


Fig. 3. Anastomosis of renal artery end-to-side to the external iliac artery.

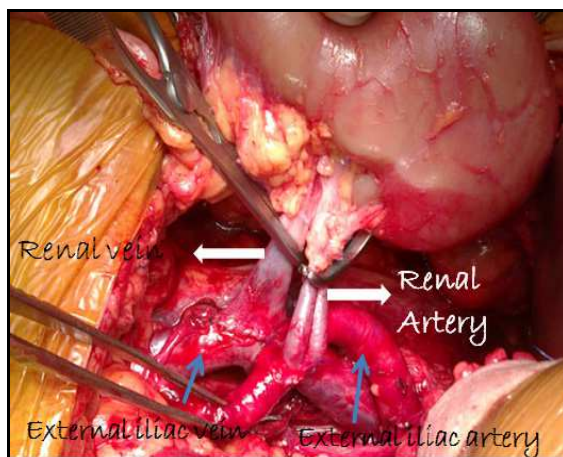
1.6 Reperfusion

The duration of arterial and venous anastomosis should not exceed 40 min. Anastomosis exceeding 40 min increases the risk of primary non-function. Before vascular clamps are opened it should be determined if there is air in the artery; when there is, heparinized solution should be injected. Additional clamps should be placed proximal to those that were

used during anastomosis and then the other clamps those used during anastomosis can be opened (Figure 4). The anastomosis region should be monitored for signs of bleeding. Bleeding usually results from a tributary vein or venous anastomosis line that is thinned due to extreme traction. If there is bleeding the site should be repaired using 5/0 or 6/0 non-absorbable sutures. After hemostasis is achieved systemic blood pressure is increased, and then the artery clamps are opened, followed by the vein clamps. When all is as it should be the renal parenchyma becomes pink and urine outflow occurs within a matter of minutes. If this is not observed, possible causes should be reviewed. For example, in marginal donor or



(a)



(b)

Fig. 4. **a.** Additional clamps can be placed proximal to the anastomosis. **b.** Before opening the clamps hemostasis must be checked.

deceased transplants blotchy areas in the kidneys may be observed due to prolonged cold ischemia and the kidneys may not be totally perfused. Surgeons must first look for a kink in the renal artery and then for pulsation of the iliac artery proximal to the anastomosis line. If there is no obvious cause the artery should be clamped distally and injected with papaverine.

After arterial and venous anastomosis, ureteral anastomosis is completed via ureteroneocystostomy or ureteroureterostomy. When the kidney is implanted in the iliac fossa, care should be taken to ascertain that the artery, vein, and ureter are correctly positioned and that there is no kink.

2. Vascular thrombosis

2.1 Renal vein thrombosis

Renal vein thrombosis (RVT) is usually seen during the first post transplantation week in 0.3%-6.1% of patients.⁶ Sudden oliguria, hematuria, pain in the transplantation region, life-threatening rupture and bleeding are clinical signs of this complication. Risk factors include surgical technique, hypercoagulopathy, right kidney transplantation, kidney transplantation in the left iliac fossa, lymphoceles, and vascular compression due to hematoma or hypovolemia. Venous thrombosis due to a short renal vein is seen more frequently in right kidney transplants.⁷ In the late posttransplantation phase the risk factors are recurrent or de novo membranous nephropathy, iliofemoral vein thrombosis, thrombophilic disorders, and CMV infection.^{8,9} With ultrasonography (US) one can observe a swollen or hypoechoic graft, a ruptured area in the cortex, lack of renal venous or arterial flow, and reverse arterial diastolic flow. Even though these findings are consistent with RVT they can be seen in cases of vascular rejection and in such cases magnetic resonance (MR) angiography can be performed for differential diagnosis.

The prognosis of RVT is poor. Acute thrombosis usually results in permanent graft loss. If RVT is suspected during the early postsurgical period additional surgery should be performed to save the graft. During such surgery the kidney should be extracted and reperfused, and should be re-implanted in the retroperitoneum after the iliac fossa is widened or implanted in the abdomen. Anastomosis should be proximal to the first anastomosis. In most center prophylactic low-dose subcutaneous heparin, sodium, or aspirin is used during the early postoperative period.¹⁰ Late-phase thromboses secondary to iliofemoral vein thrombosis, de novo membranous nephropathy, and thrombophilic disorders are extremely rare; percutaneous interventions are commonly used to treat such complications.

2.2 Renal artery thrombosis

2.2.1 Etiology

Arterial thrombosis occurs in <1% of renal transplant patients.^{11,12} The first sign of arterial thrombosis is a sudden decrease in urine outflow; physicians should be aware that in cases in which the native kidney is producing urine and there is a delay in graft function, this early sign could be masked. The most common causes of renal artery thrombosis are technical. During nephrectomy in living donors or cadavers an intimal flap in the renal artery, occlusion due to atherom plaque in the recipient internal iliac artery or renal artery

ostium, and torsion or kinking of the anastomosis can result in thrombosis. Other more rare causes include immunological reactions, hypercoagulopathy, cryoglobulin and anti-phospholipid antibodies associated with hypercoagulopathy and observed in active lupus erythematosus patients, and thrombogenic drugs such as cyclosporin and monoclonal antibody OKT-3.^{10,13}

2.2.2 Diagnosis

In all patients prerenal and post-renal causes of thrombosis should be investigated before transplantation. Hypovolemia due to prerenal reasons or hypoperfusion resulting from congestive heart disease should be excluded. Obstruction should be excluded by inserting a foley catheter. Moreover, the vascular tree should be evaluated for thrombosis. Color Doppler US is a useful investigative tool that not only shows renal artery and vein flow, but also facilitates calculation of the intraparenchymal resistance index. Angiography, which is useful for evaluating renal artery stenosis, is seldom used for investigating thrombosis. Between the onset of arterial thrombosis and its diagnosis infarcts and necrosis can develop. Most cases eventually undergo nephrectomy as a result. Allograft loss due to thrombosis rarely occurs, but its consequences are serious.

2.2.3 Treatment and prevention

Treatment of thrombosis is urgent exploration of the renal artery. In most cases the time from diagnosis to surgery is so long that necrosis occurs and nephrectomy is required. During exploration if the anastomosis line and cortical perfusion are observed to be normal Doppler US investigation and intraoperative renal biopsy should be performed. Allograft loss due to thrombosis is rare, but serious. Epidemiologic research shows that thrombotic risk factors are divided into 2 groups: those that can be modified (dialysis, drugs, and surgery) and those that cannot be modified: (age, diabetes mellitus, and vascular anomalies). It was also reported that in the first postoperative month the risk of thrombosis is higher in patients that undergo preoperative peritoneal dialysis and retansplant.¹⁴

Acetylsalicylic acid, low molecular weight heparin, and unfractionated heparin are used to prevent vascular thrombosis. It is reported that heparin, warfarin, and acetylsalicylic acid given in the early postoperative period decreases the vascular thrombosis rate, but increases the bleeding rate.¹⁵⁻¹⁷ These studies were retrospective case-control studies and the reliability, efficacy, and optimal utilization time of such agents that prevent allograft thrombosis as acetylsalicylic acid and heparin can only be ascertained by large, multicenter randomized studies.

2.2.4 Prevention strategies

1. The most common cause of thrombosis is surgical technique. Attention should be paid to the anastomosis technique and vascular dissection; in particular, the intimal layer must not be damaged.
2. Acute tubular necrosis, one of the causes of vascular thrombosis, may be prevented by minimizing the duration of hot and cold ischemia.
3. Early diagnosis of vascular or antibody-mediated rejection, and treatment reduces the risk of both endothelial and vascular thrombosis.

4. In patients with a high risk of thrombosis low molecular weight heparin, warfarin, or acetylsalicylic acid should be administered during the early postoperative period.

3. Renal artery stenosis

The most important vascular complication during the late postsurgical period is renal artery stenosis, which has an incidence rate of 2%-8%, but has also been reported to be as high as 23%.^{18,19} Its signs are poor renal function test results, sudden onset of resistant hypertension, and life-threatening congestive heart failure.²⁰ Most patients are investigated due to an initial diagnosis of rejection. Some patients with renal artery stenosis are asymptomatic. In asymptomatic renal transplant recipients renal artery stenosis is 12.4% based on routine Doppler screening, versus 2.4% in symptomatic patients.²¹ Renal artery stenosis occurs in the anastomosis region most frequently between post transplant month 3 and year 2, although it can be pre- or post-anastomosis in origin. The incidence of renal artery stenosis is higher in cases of end-to-end anastomosis.

There are 3 types of renal artery stenosis: anastomotic, diffuse post-anastomotic, and widespread restriction in the distal arterial bed. The etiology of the anastomotic type is the restriction effect of the suture, and injury to donor vessels during nephrectomy. Intimal flaps in the vessel wall and subintimal dissection lead to intimal injury and hyperplasia. A kink in the artery or angulation when the kidney is being implanted leads to turbulent flow and stenosis in the anastomosis. The diffuse post-anastomotic type of stenosis can affect different regions of the artery (multiple stenosis), as well as the entire artery (diffuse stenosis). De novo (previously present) atherosclerosis in donor vessels can cause diffuse stenosis in the long term under the influence of immunosuppressive agents. The third type of stenosis—widespread stenosis in the distal arterial bed—usually occurs due to immune-mediated endothelial injury. Cytomegalovirus (CMV) leads to renal artery stenosis due to endothelial injury via proliferation in smooth muscle cells.

Renal artery stenosis during the late post transplant period is most often seen in kidneys with multiple renal arteries. The stenosis rate (0%) for anastomoses performed via the aortic patch technique is much lower than that (5%) observed in anastomoses performed via techniques other than the patch.²² The aortic patch is specific to cadaveric transplantation.

3.1 Diagnosis

Doppler US, CT angiography, MR angiography, and angiographic imaging methods can be used to diagnose renal artery stenosis; however, angiography is the gold standard. Doppler US is routinely used to evaluate transplanted kidney parenchyma and vascular structures, and must be performed by experienced personnel in order to achieve optimum results. In Doppler US, peak systolic velocity $>2.5 \text{ m s}^{-1}$ in the stenotic region is significant for renal artery stenosis. In a region close to the anastomosis site an iliac artery peak systolic velocity to renal artery velocity ratio >2 suggests stenosis.²³ Patients suspected to have stenosis based on Doppler US should be evaluated with CT angiography, which provides valuable information about the location and extent of renal artery stenosis. Before CT angiography adequate hydration and N-acetylcysteine should be given in order to prevent contrast-induced nephropathy. Definitive diagnosis of renal artery stenosis is made based on renal angiography.

3.2 Treatment

Treatment of renal artery stenosis can be conservative (in cases in which graft perfusion is normal) or revascularization (surgery or percutaneous transluminal angioplasty [PTA]) can be performed. If stenosis is $\leq 60\%$, renal function is normal, and arterial hypertension is manageable with medical therapy, patients can be followed-up with Doppler US. In cases in which medical therapy is inadequate PTA (with or without stenting) is the treatment of choice (Figure 5). In cases with stenosis of the hilar region or distal renal bed, PTA is the preferred treatment option. Success rate of PTA/stenting was 60%-94%, the complication rate was 0.8%-3%, and 1 year post procedure 85% of stents remained unoccluded.^{24,25}

Permanent treatment of renal artery stenosis is surgery. PTA is not the treatment of choice in patients with renal artery stenosis due to arterial kinks or atherosclerotic diseases; in such patients surgical intervention should be performed. Surgery involves removal of the stenotic segment and re-anastomosis to the external iliac artery or anastomosis to the internal iliac artery using the saphenous vein. In cases of post-anastomotic stenosis the bypass grafting technique is used via autogenous graft. The surgical success rate varies between 63% and 92%,²⁶ and in 10%-12% of patients restenosis occurs within the first 8-9 months following surgery.²⁷

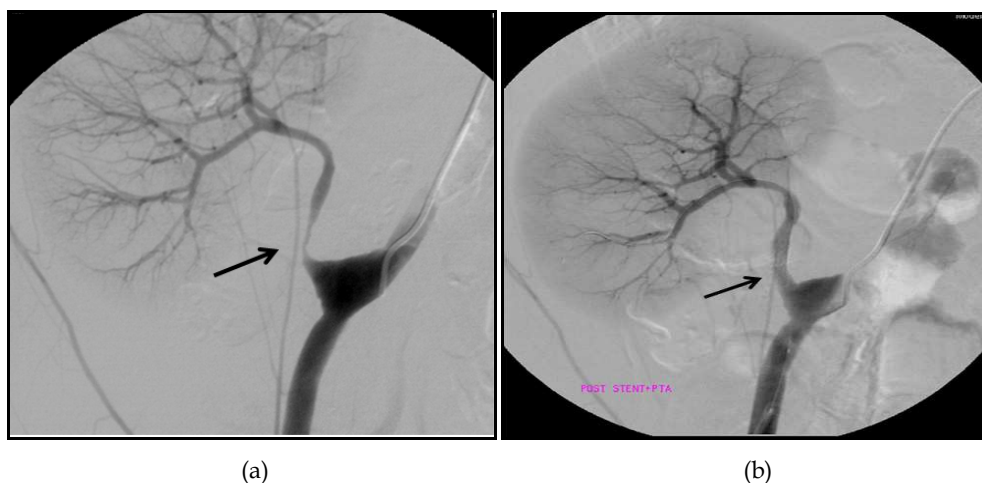


Fig. 5. **a.** Conventional angiography shows stenosis of the renal artery in a kidney transplant patient (arrow) **b.** Post-PTA conventional angiography shows successful stent implantation at the renal artery stenotic segment (arrow).

4. Summary

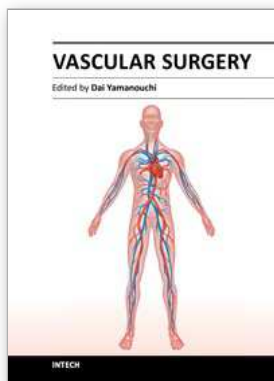
Renal transplantation is the treatment of choice for end-stage renal disease. Despite medical and surgical advances, vascular complications after kidney transplantation remain an important clinical problem that may increase morbidity, hospitalization and costs. Vascular complications in renal transplantation are not uncommon and may often lead to allograft loss. The most common vascular complications are renal artery stenosis, renal artery thrombosis and renal vein thrombosis. Transplant renal artery and vein thrombosis have an

early onset and a dramatic clinical manifestation and usually lead to allograft loss. These complications may compromise graft function and cause significant morbidity. Therefore, knowledge of the incidence, clinical manifestations and management of vascular complications is necessary for all kidney transplant surgeons.

5. References

- [1] Kobayashi K, Censullo ML, Rossman LL, et al: Interventional radiologic management of renal transplant dysfunction: indications, limitations, and technical considerations. *Radiographics* 27:1109, 2007.
- [2] Paul J. Phelan, William Shields, Patrick O'Kelly et al. Left versus right deceased donor renal allograft outcome *Transpl Int.* 2009;22(12):1159-63.
- [3] Parrott NR, Forsythe JL, Matthews JN, et al: Late perfusion: a simple remedy for renal allograft primary nonfunction. *Transplantation* 49:913-915, 1990.
- [4] J.K. Hwang, S.D. Kim, S.C. Park, The Long-Term Outcomes of Transplantation of Kidneys With Multiple Renal Arteries. *Transplantation Proceedings*, 42, 4053-4057 (2010).
- [5] Hwang JK, Kim SD, Park SC, Choi BS, Kim JI, Yang CW, Kim YS, Moon IS. The long-term outcomes of transplantation of kidneys with multiple renal arteries. *Transplant Proc.* 2010 Dec;42(10):4053-7.
- [6] Obed A, Uihlein DC, Zorger N, et al: Severe renal vein stenosis of a kidney transplant with beneficial clinical course after successful percutaneous stenting. *Am J Transplant.* 8:2173, 2008.
- [7] Takahashi M, Humke U, Girndt M, Kramann B, Uder M. Early posttransplantation renal allograft perfusion failure due to dissection: diagnosis and interventional treatment. *AJR Am J Roentgenol* 2003; 180: 759-763.
- [8] Kazory A, Ducloux D, Coaquette A, Manzoni P, Chalopin JM. Cytomegalovirus-associated venous thromboembolism in renal transplant recipients: a report of 7 cases. *Transplantation* 2004;77:597-599.
- [9] Hausmann MJ, Vorobiov M, Zlotnik M, Rogachev B, Tomer A. Increased coagulation factor levels leading to allograft renal vein thrombosis. *Clin Nephrol* 2004;61:222-224.
- [10] Irish A. Hypercoagulability in renal transplant recipients. Identifying patients at risk of renal allograft thrombosis and evaluating strategies for prevention. *Am J Cardiovasc Drugs.* 2004;4(3):139-49.
- [11] M.L. Melamed, H.S. Kim and B.G. Jaar et al., Combined percutaneous mechanical and chemical thrombectomy for renal vein thrombosis in kidney transplant recipients, *Am J Transplant* 5 (2005), p. 621.
- [12] Obed, D.C. Uihlein and N. Zorger et al., Severe renal vein stenosis of a kidney transplant with beneficial clinical course after successful percutaneous stenting, *Am J Transplant* (2008), p. 2173.
- [13] Bombeli T, Muller M, Straub PW, Haeberli A. Cyclosporine - induced detachment of vascular endothelial cells initiates the intrinsic coagulation system in plasma and whole blood. *J Lab Clin Med* 1996; 127:621 - 634.
- [14] R. Palomar, P. Morales, E. Rodrigo et al. Venous Graft Thrombosis in Patients on Peritoneal Dialysis Before Transplantation *Transplantation Proceedings*, 39, 2128-2130 (2007).

- [15] Humar A, Key N, Ramcharan T, Payne WD, Sutherland DER, Matas AJ. Kidney transplants after initial graft loss to vascular thrombosis. *Clin Transplant* 2001; 15: 6-10.
- [16] Paul E. Morrissey, Pedro J. Ramirez, Reginald Y. Gohh. et al. Management of Thrombophilia in Renal Transplant Patients *American Journal of Transplantation* 2002; 2: 872-876
- [17] Boughey JC, Bowen PA 2nd, Gifford RR Renal transplantation in patients with hypercoagulable states. *J S C Med Assoc.* 2003 Dec;99 (12):372-4.)
- [18] Osman Y, Shokeir A, Ali - el - Dein B, et al. Vascular complications after live donor renal transplantation: study of risk factors and effects on graft and patient survival. *J Urol* 2003; 169: 859 - 862.
- [19] Patel NH, Jindal RM, Wilkin T, et al: Renal arterial stenosis in renal allografts: retrospective study of predisposing factors and outcome after percutaneous transluminal angioplasty. *Radiology* 219:663, 2001.
- [20] Garovic VD, Textor SC: Renovascular hypertension and ischemic nephropathy. *Circulation* 112:1362-1374, 2005.
- [21] Wong W, Fynn SP, Higgings RM, et al. Transplant renal artery stenosis in 77 patients: does it have an immunological cause? *Transplantation* 61: 1996;215-219.
- [22] Fung LC, McLorie GA, Khoury AE, Churchill BM. Donor aortic cuff reduces the rate of anastomotic arterial stenosis in pediatric renal transplantation. *J Urol* 1995;154: 909-91.
- [23] Cosgrove D, Chan K. Renal transplants: What ultrasound can and cannot do. *Ultrasound Quarterly* 2008;24:77-87.
- [24] Peregrin JH, Stríbrná J, Lácha J, et al: Long-term follow-up of renal transplant patients with renal artery stenosis treated by percutaneous angioplasty. *Eur J Radiol* 66:512, 2008
- [25] Patel NH, Jindal RM, Wilkin T, et al: Renal arterial stenosis in renal allografts: retrospective study of predisposing factors and outcome after percutaneous transluminal angioplasty. *Radiology* 219:663, 2001.
- [26] Benoit G, Moukarzel M, Hiesse C, et al: Transplant renal artery stenosis: experience and comparative results between surgery and angioplasty. *Transpl Int* 3:137, 1990.
- [27] Aktas, F. Boyvat, S. Sevmis. et al. Analysis of Vascular Complications After Renal Transplantation. *Transplantation Proceedings*, 43, 557-561 (2011).



Vascular Surgery

Edited by Dr. Dai Yamanouchi

ISBN 978-953-51-0328-8

Hard cover, 262 pages

Publisher InTech

Published online 04, April, 2012

Published in print edition April, 2012

This book aims to provide a brief overview of conventional open vascular surgery, endovascular surgery and pre- and post-operative management of vascular patients. The collections of contributions from outstanding vascular surgeons and scientists from around the world present detailed and precious information about the important topics of the current vascular surgery practice and research. I hope this book will be used worldwide by young vascular surgeons and medical students enhancing their knowledge and stimulating the advancement of this field.

How to reference

In order to correctly reference this scholarly work, feel free to copy and paste the following:

Taylan Ozgur Sezer and Cuneyt Hoscoskun (2012). Vascular Complications After Renal Transplantation, Vascular Surgery, Dr. Dai Yamanouchi (Ed.), ISBN: 978-953-51-0328-8, InTech, Available from: <http://www.intechopen.com/books/vascular-surgery/vascular-complications-after-renal-transplantation>

INTECH

open science | open minds

InTech Europe

University Campus STeP Ri
Slavka Krautzeka 83/A
51000 Rijeka, Croatia
Phone: +385 (51) 770 447
Fax: +385 (51) 686 166
www.intechopen.com

InTech China

Unit 405, Office Block, Hotel Equatorial Shanghai
No.65, Yan An Road (West), Shanghai, 200040, China
中国上海市延安西路65号上海国际贵都大饭店办公楼405单元
Phone: +86-21-62489820
Fax: +86-21-62489821