Para follicular cells (C cells) :

- Derived from ultimobranchial body from Ventral part of 4th (5th) pharyngeal pouch
- calcitonin

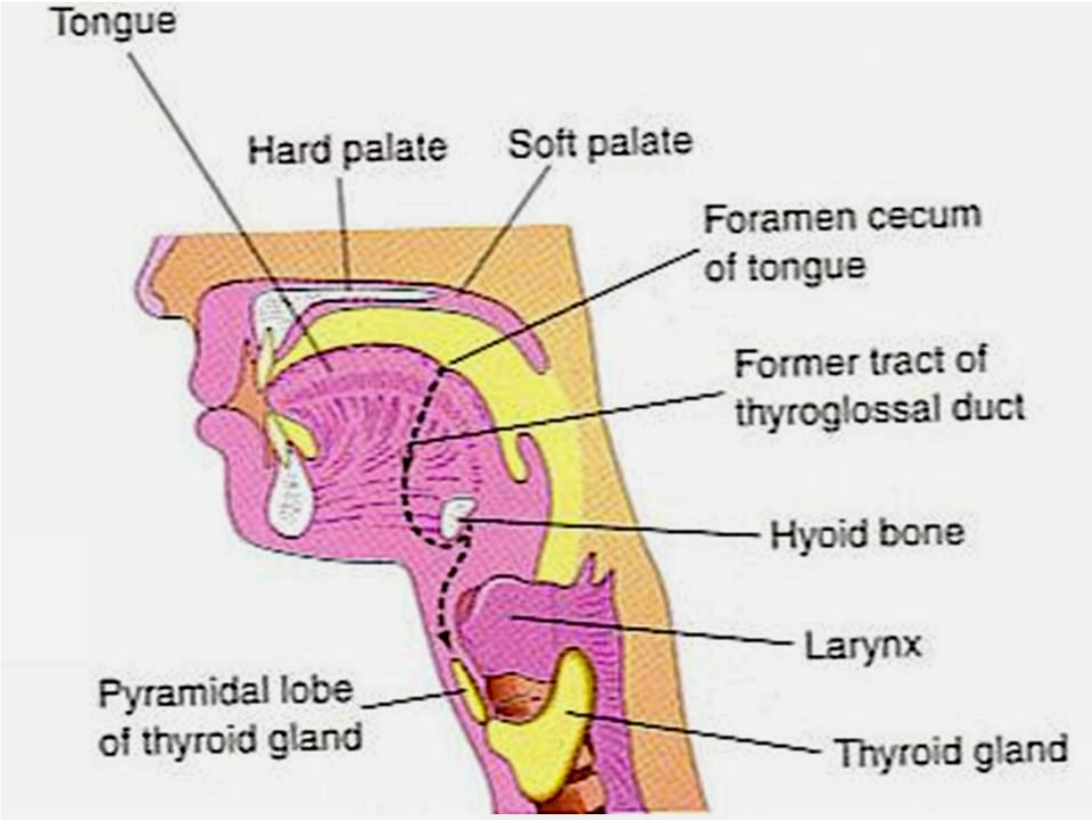

Thyroglossal cyct:

path of thyroid descending

Position of occur:

Inf. To the body of hyoid 50%
Base of tongue
Close to thyroid cartilage

Thyroglossal fistula

Abberant thyroid tissue:

path of thyroid descending
Base of tongue

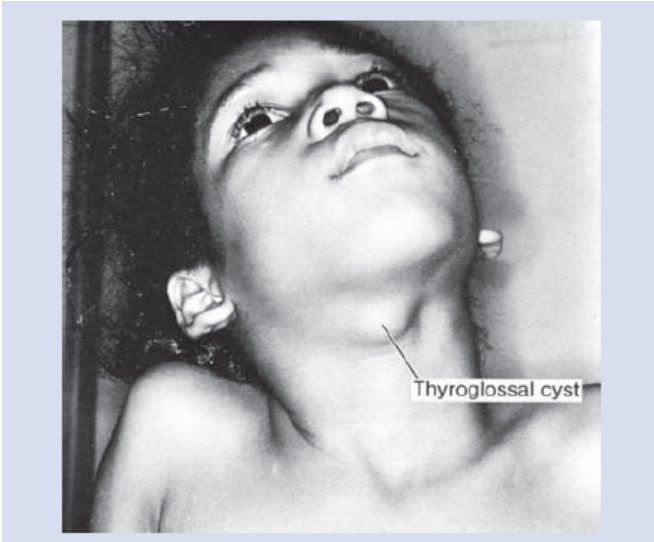

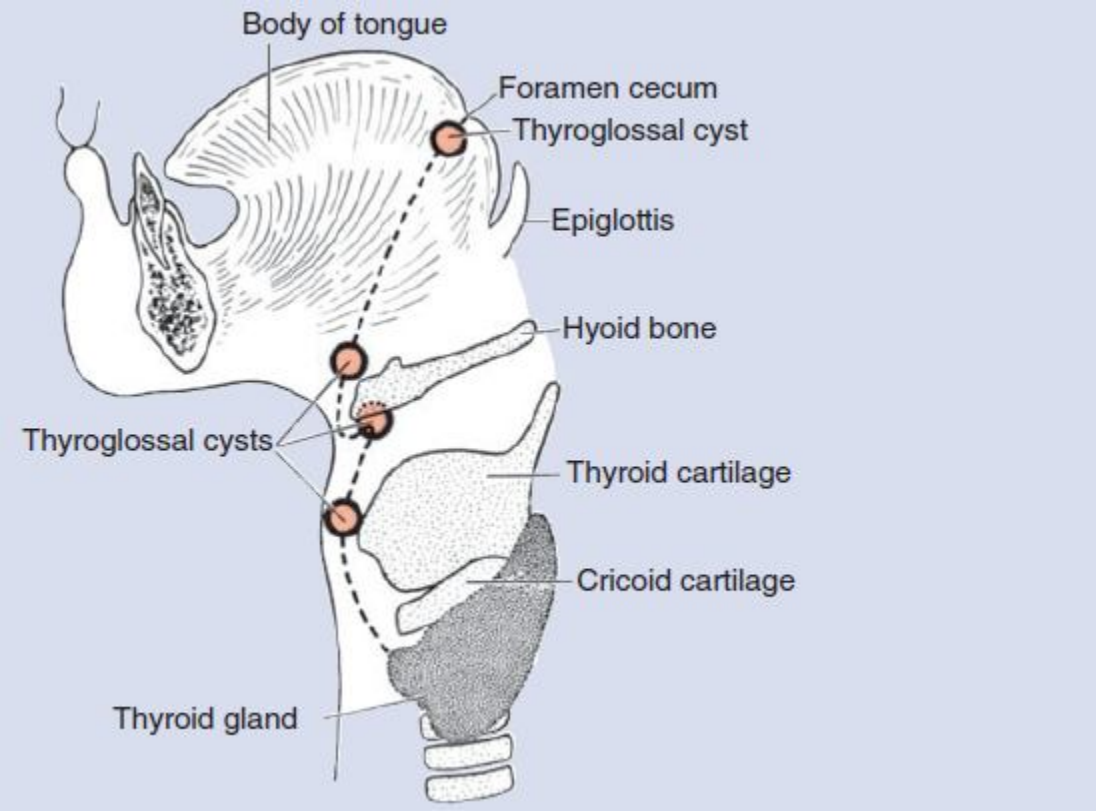

Histology of the thyroid gland

Thyroid gland:

Capsule / trabeculae
Follicles / reticular fiber / basal lamina
Follicular cells/ basal lamina
parafollicular cells
Colloid (***hormone storage***)

Produce energy & temperature for body activity

parafollicular cells:

Decreased Ca^{+} in blood by 2 ways:

1. Transport Ca from blood to musculoskeletal system
2. Prevent bone absorption by osteoclast cells

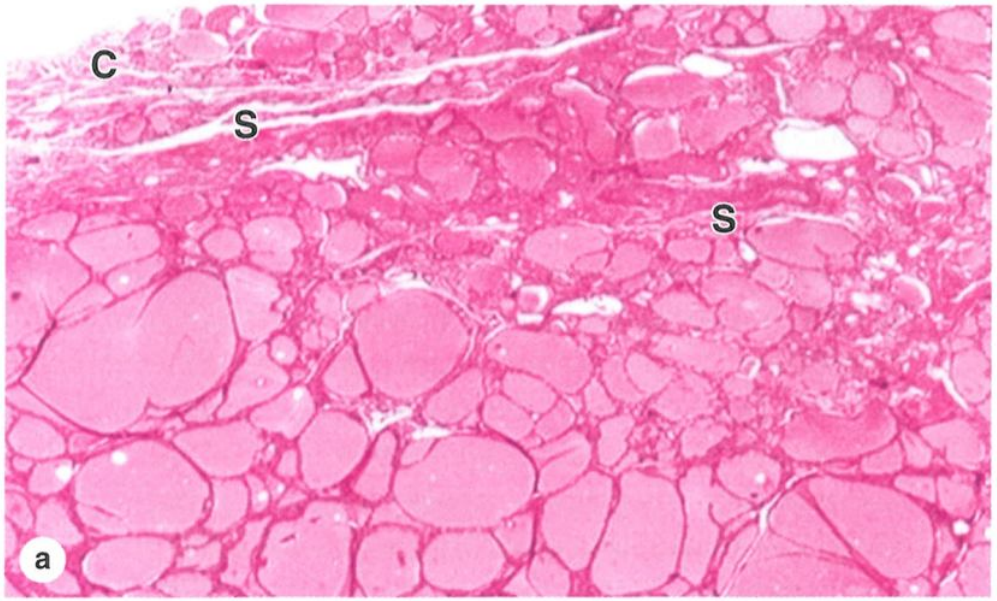

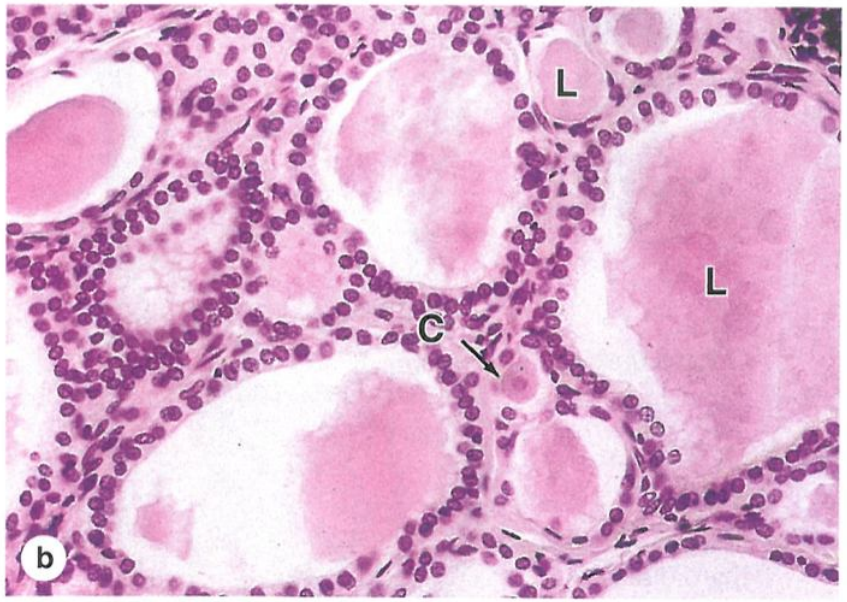

Histology of the thyroid gland

Thyroid hormones:

Tri-iodothyronin
Tetra-iodothyronin
Calcitonin

- Fenestrated capillary

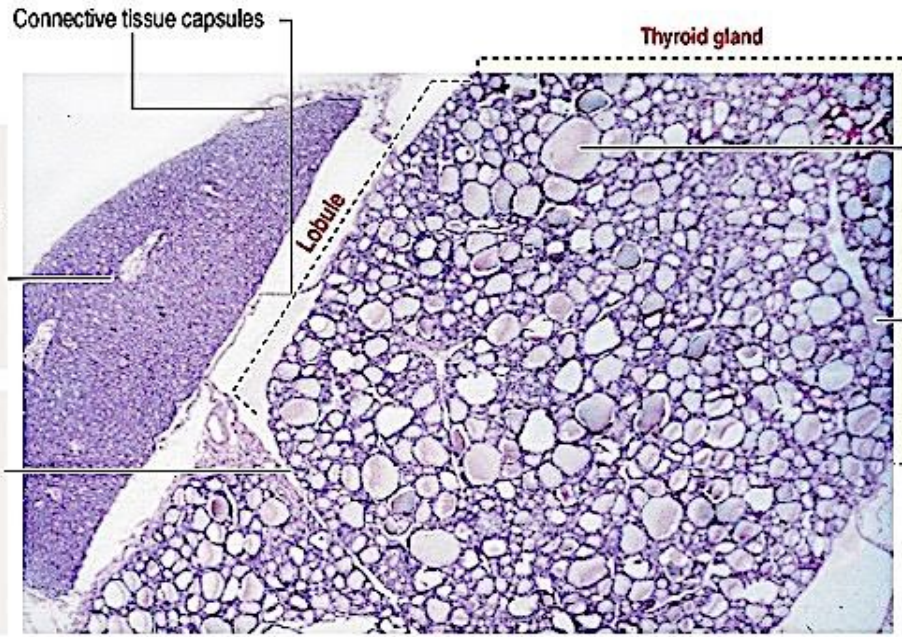

Parathyroid gland The parathyroid glands are separated from the capsule of the thyroid gland by their own connective tissue capsules.

Septum The connective tissue capsule extends septa into the mass of the gland, which is subdivided into incomplete lobules.

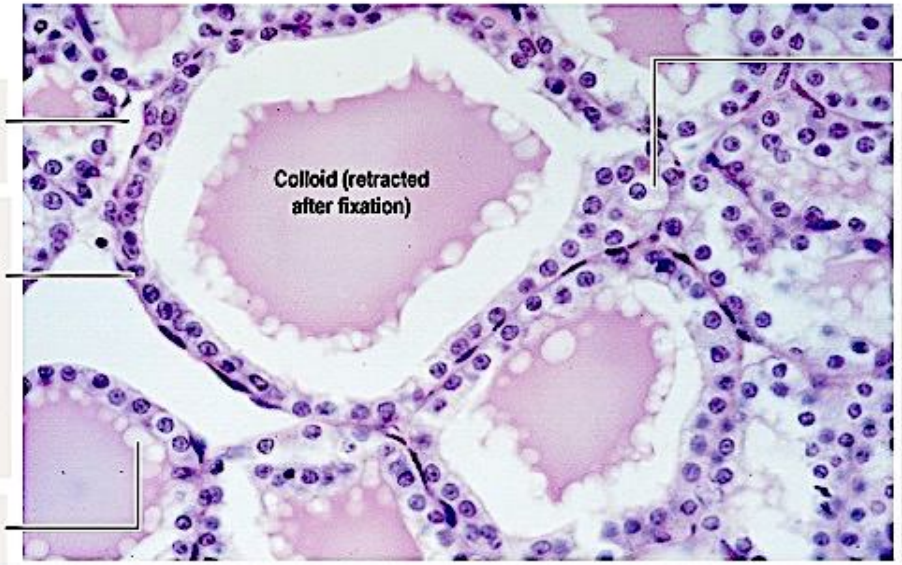

Blood vessels are found around the follicles.

Follicular epithelium In the inactive follicle, the follicular epithelium is simple low cuboidal, or squamous. During their active secretory phase, the cells become columnar.

Area of colloid resorption

A **C cell** can be distinguished from surrounding follicular cells by its pale cytoplasm.

Two more effective identification approaches are:
1. Immunocytochemistry, using an antibody to calcitonin.
2. Electron microscopy, to visualize calcitonin-containing cytoplasmic granules.

Synthesis and secretion of thyroid hormones T_3 and T_4

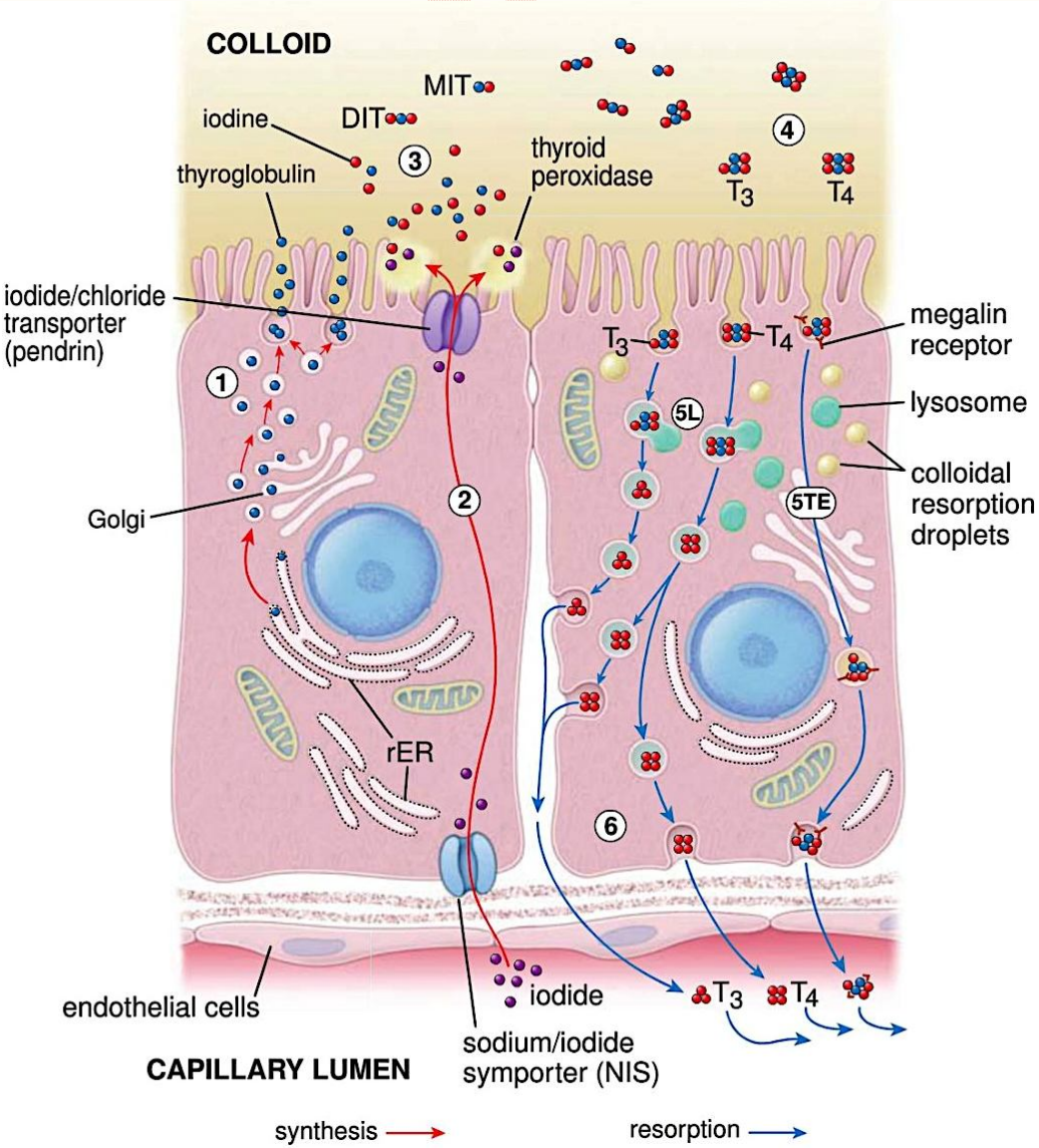

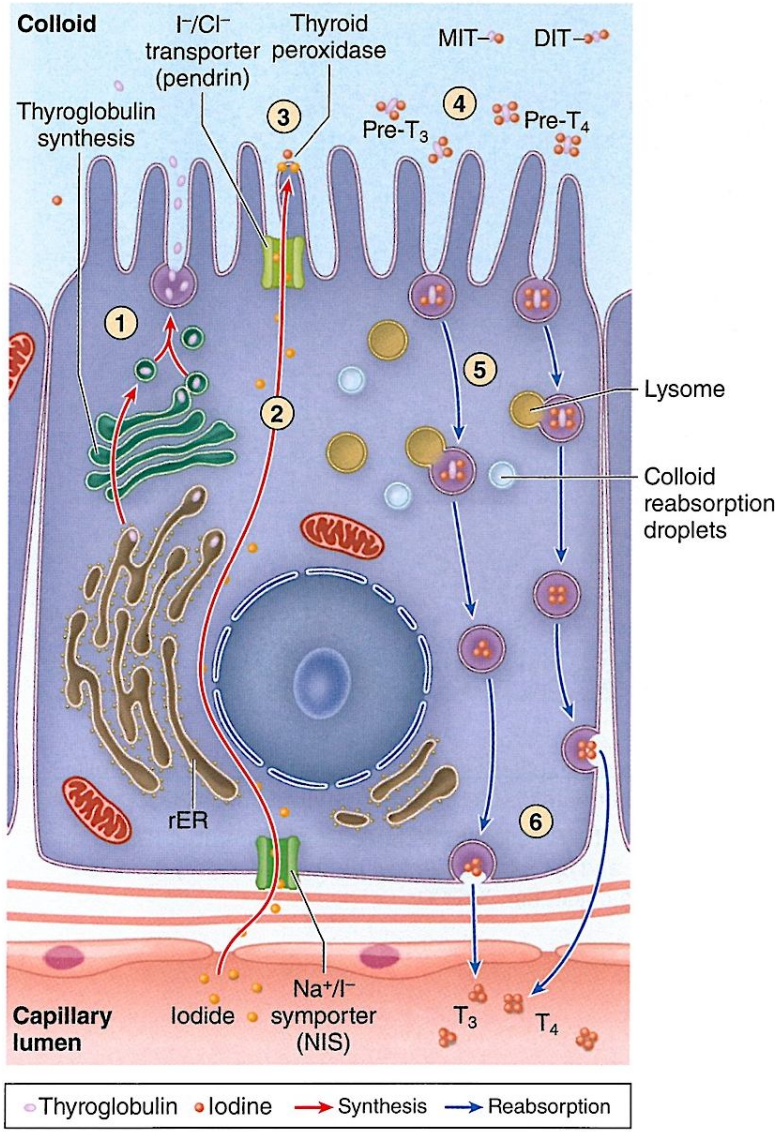

Synthesis and secretion of thyroid hormones T_3 and T_4

4 At the **apical plasma membrane**, **thyroid peroxidase** is activated and converts **iodide** into **iodine**. Two iodine atoms are linked to each tyrosyl residue. Iodination occurs within the lumen of the thyroid follicle.

After proteolytic processing, one monoiodotyrosine peptide combines with diiodotyrosine to form **T_3 (triiodothyronine)**. Two diiodotyrosines combine to form **T_4** (thyroxine). One iodinated thyroglobulin molecule yields four molecules of T_3 and T_4.

Clinical significance: Propylthiouracil and **methyl mercaptoimidazole** (MMI) inhibit thyroid peroxidase–mediated iodination of tyrosine in thyroglobulin.

5 A droplet in the colloid of the thyroid follicle, containing iodinated thyroglobulin, is endocytosed by a **pseudopod** extension of the apical domain of a follicular epithelial cell. The **intracellular colloid droplet**, guided by cytoskeletal components, fuses with a **lysosome**. T_3 and T_4 molecules are released by the proteolytic action of lysosomal enzymes.

Clinical significance: Propylthiouracil can block the conversion of T_4 to T_3 in peripheral tissues (liver).

3 **Thyroglobulin** is a glycoprotein (660 kd) consisting of two identical subunits. Thyroglobulin contains 140 tyrosyl residues available for iodination.

2 **Membrane-bound thyroid peroxidase** and **thyroglobulin** are present in the same secretory vesicle.

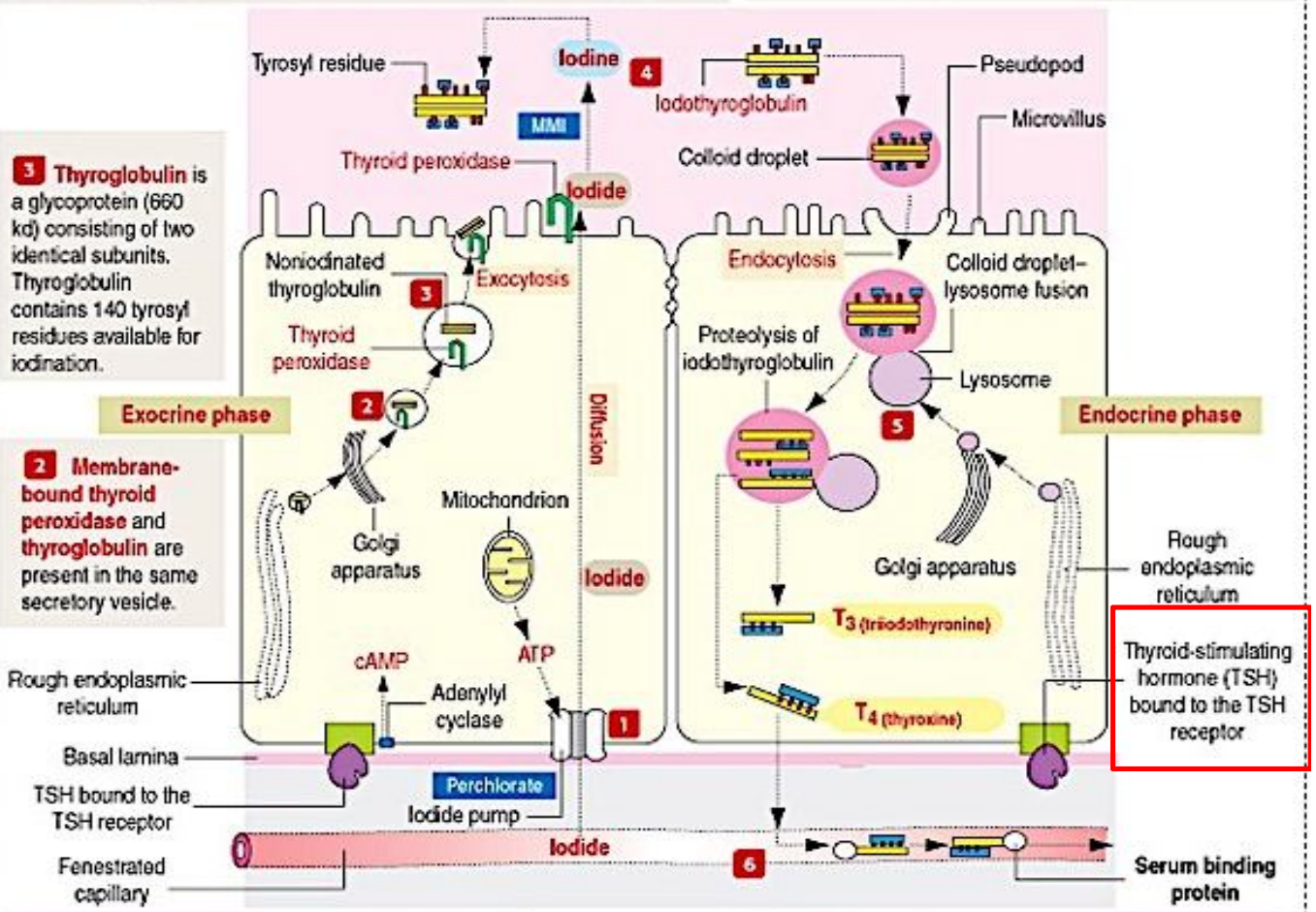

1 The **iodide pump** concentrates iodide within the thyroid follicular cell 20- to 100-fold above serum levels.

An Na+, K+-dependent ATPase and adenosine triphosphate (ATP) provide the energy for iodide transport.

Clinical significance: The iodide pump can be inhibited by **perchlorate**, a competitive anion.

6 **T_3** and **T_4** are released from the cell across the basal lamina of the thyroid follicle into a **fenestrated capillary** and bind to **serum binding proteins**.

T_3 has a shorter half-life (18 hours) than T_4 (5 to 7 days). T_3 is 2 to 10 times more active than T_4.

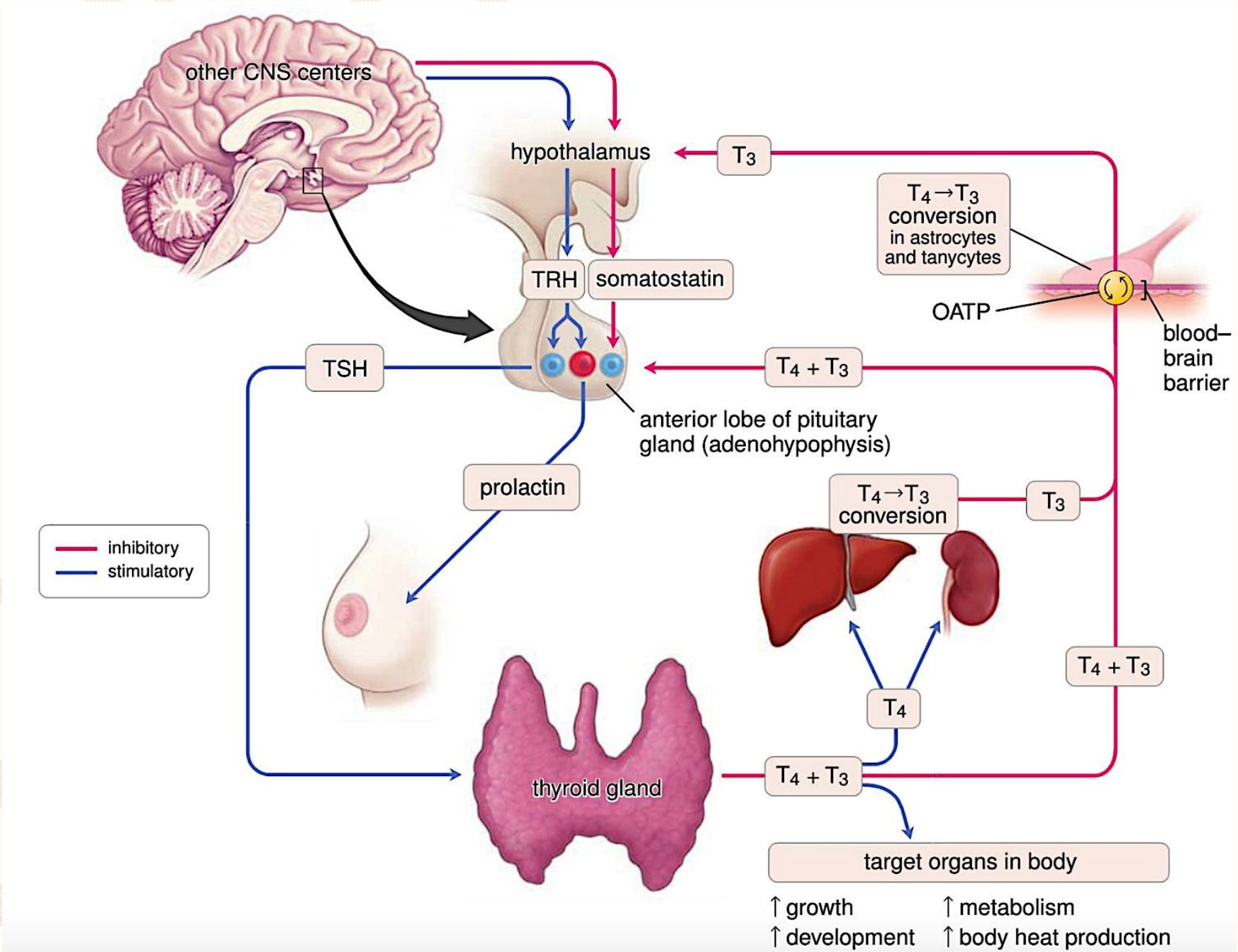
other CNS centers
hypothalamus
T3
T4→T3 conversion in astrocytes and tanycytes
OATP
blood–brain barrier
TRH
somatostatin
TSH
T4 + T3
anterior lobe of pituitary gland (adenohypophysis)
prolactin
T4→T3 conversion
T3
inhibitory
stimulatory
T4 + T3
T4
thyroid gland
T4 + T3
target organs in body
↑ growth
↑ development
↑ metabolism
↑ body heat production

Synthesis and mechanism of action of calcitonin

Parafollicular cell (C cell):

Located in basal lamina of follicular epithelium / between follicular cells
Pale cells / larger than follicular cells
Low ER / large Golgi / many granules
↑ plasma Ca2 + = activate parafollicular cells = calcitonin secretion = suppress osteoclast activity

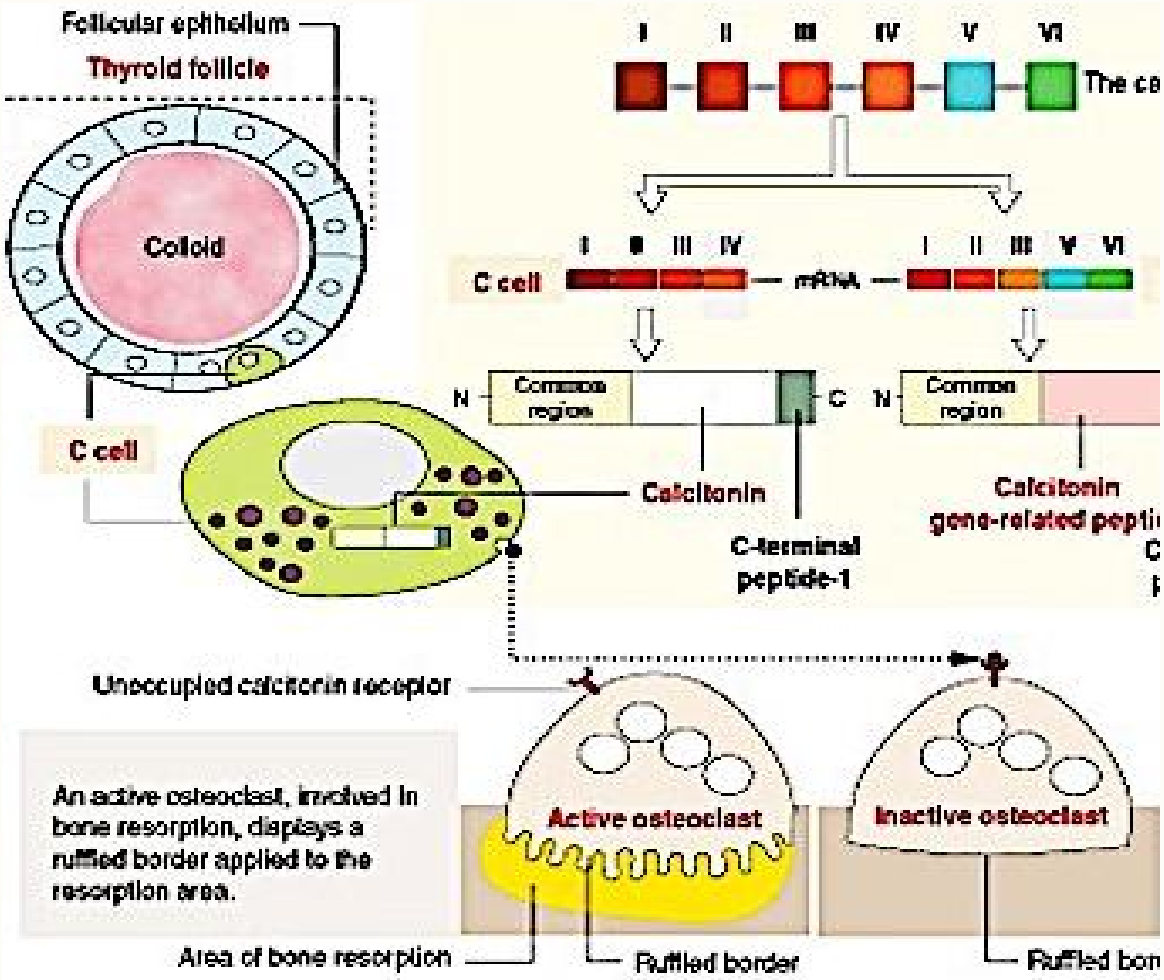

Gravies disease (exophthalmic goiter / toxic goiter):

- excessive amounts of thyroid hormones are released into the circulation
- detectable levels of autoantibodies
- abnormal immunoglobulins (IgG) bind to the TSH receptor
- in-creased thyroid hormone secretion
- Because of negative feedback, the levels of TSH in the circulation are usually normal
- Hypertrophy
- thyroid hormone Is abnormally high range
- increased metabolism

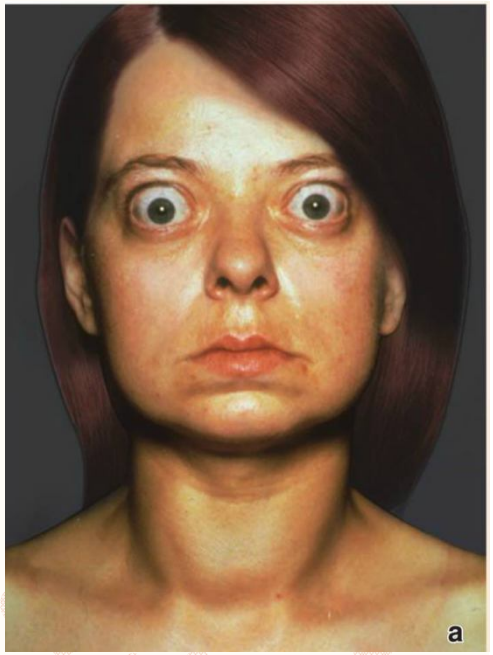

- Features:

weight loss / excessive sweating / tachycardia /nervousness / protrusion of the eyeballs / retraction of the eyelids

- resulting from increased sympathetic activity / increased deposition of extracellular matrix in the adipose tissue located behind the eyeball

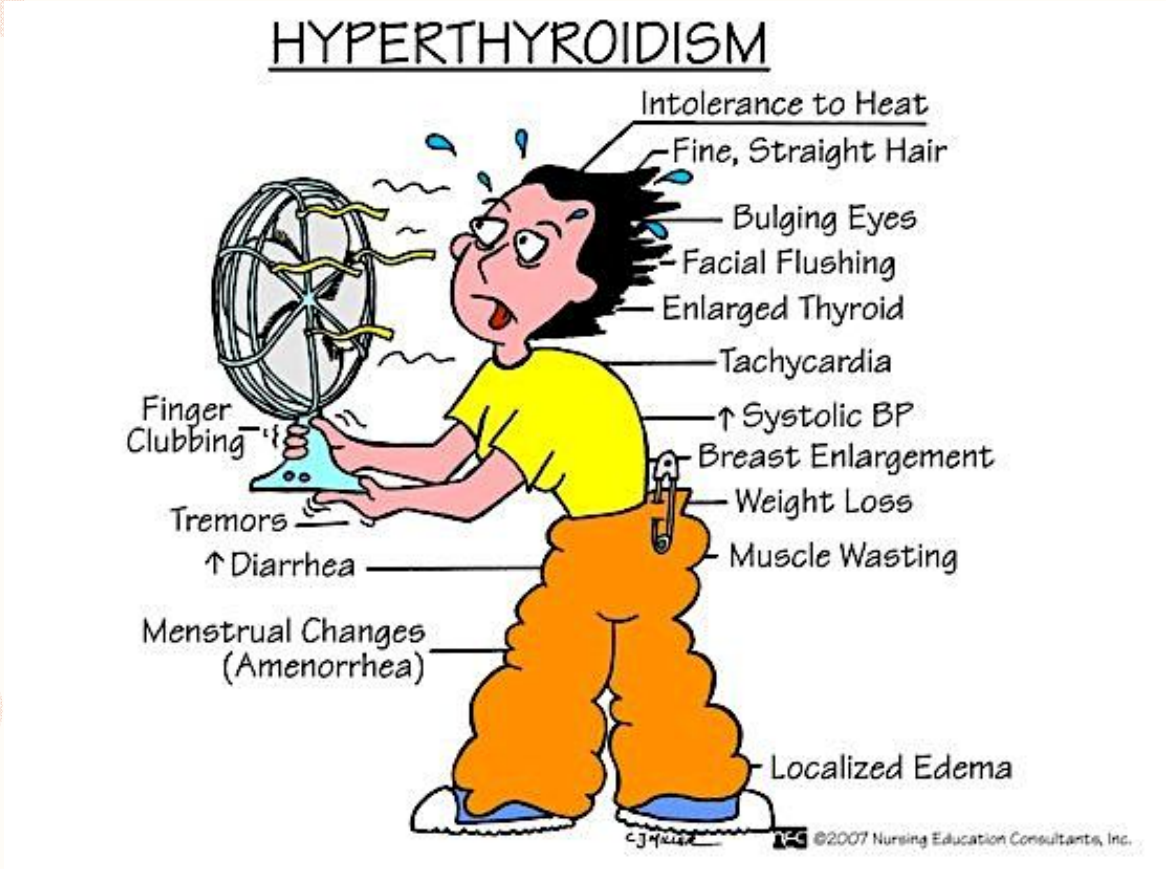

Hypothyroidism :

In adult:
Myxedema (mucopolysaccharidedeposits in the skin) / fatigue / Feeling cold /Weight gain with poor appetite

In children:
Cretinism

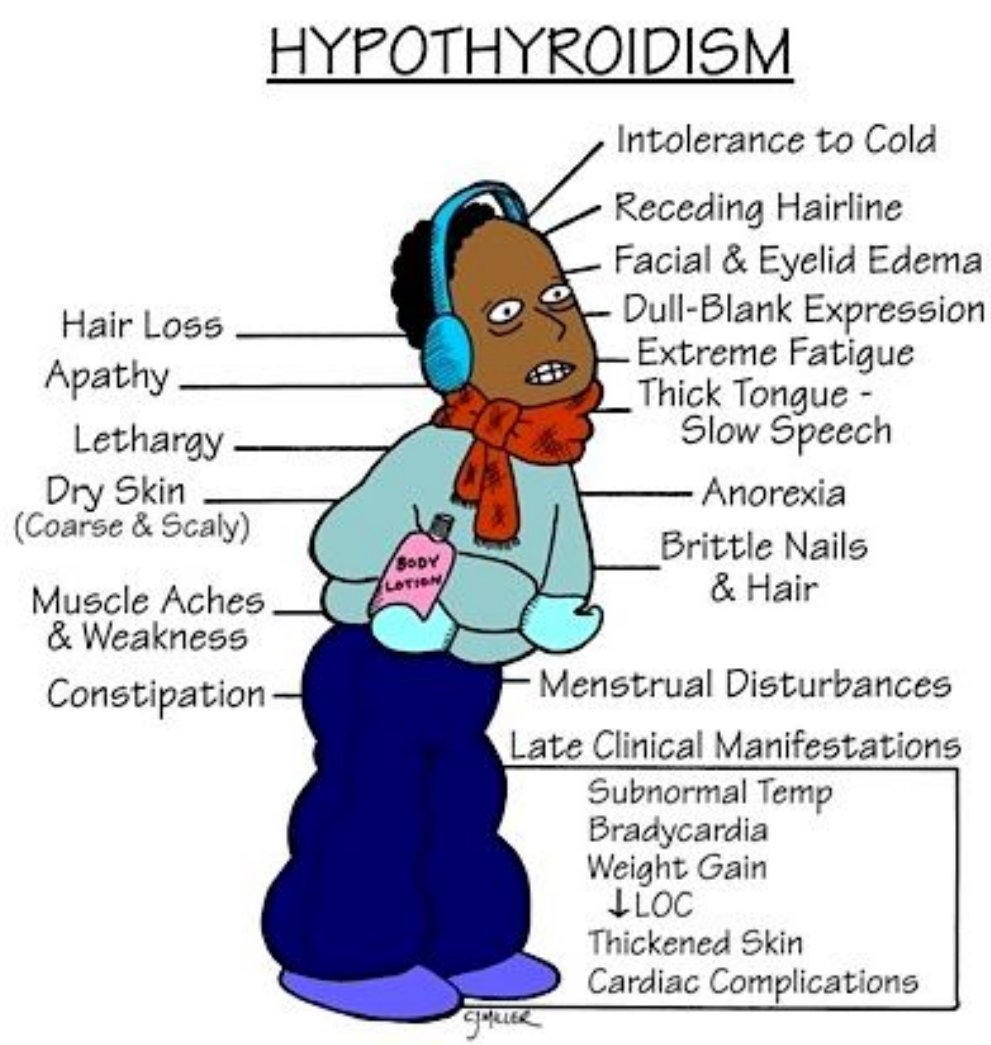

Simple goiter:

- Lake of iodine in diet
- Lake of thyroid hormones
- Increase TSH
- Increase thyroglobulin synthesis
- Gland enlargement

Neuro endocrine
&
Endocrine

Hypophysis gland

Pineal body

Pancreatic islets

Thyroid gland

Parathyroid gland

Suprarenal gland

Parathyroid gland

- 50 mg
- Located on post. Border of thyroid gland
- Consist of 4 glands
- yel-lowish structures
- designated as the superior and inferior parathyroid glands
- surrounded by a thin connective tissue capsule that separates it from the thyroid
- Septa extend from the capsule into the gland to divide it into poorly defined lobules

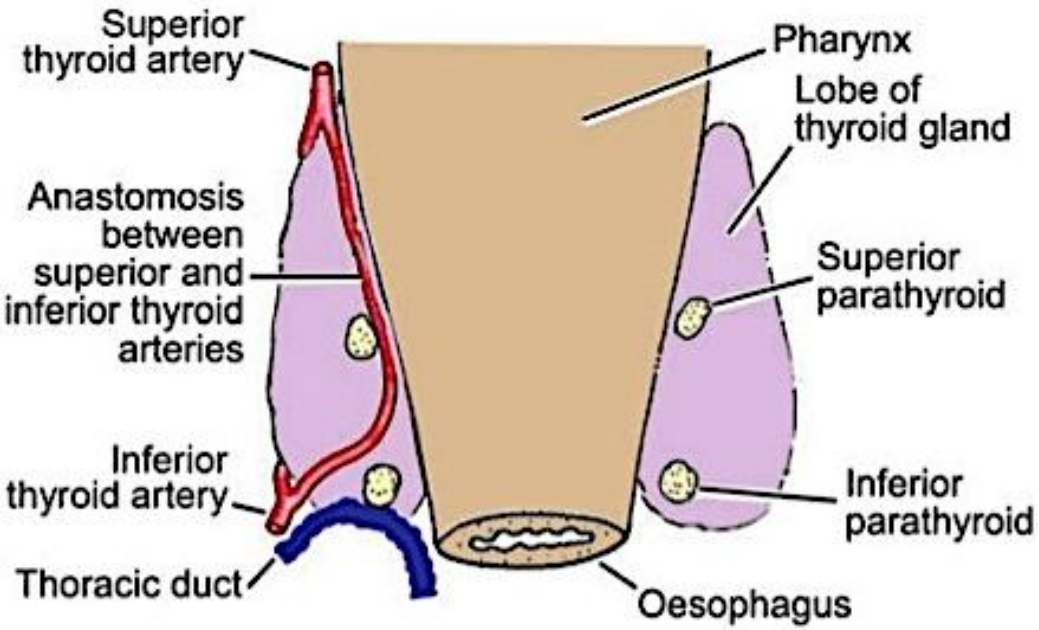

46.10: Thyroid and parathyroid glands seen from behind

The arteries :

- the inferior thyroid arteries
- venous and lymphatic drain-age follows that described for the thyroid gland

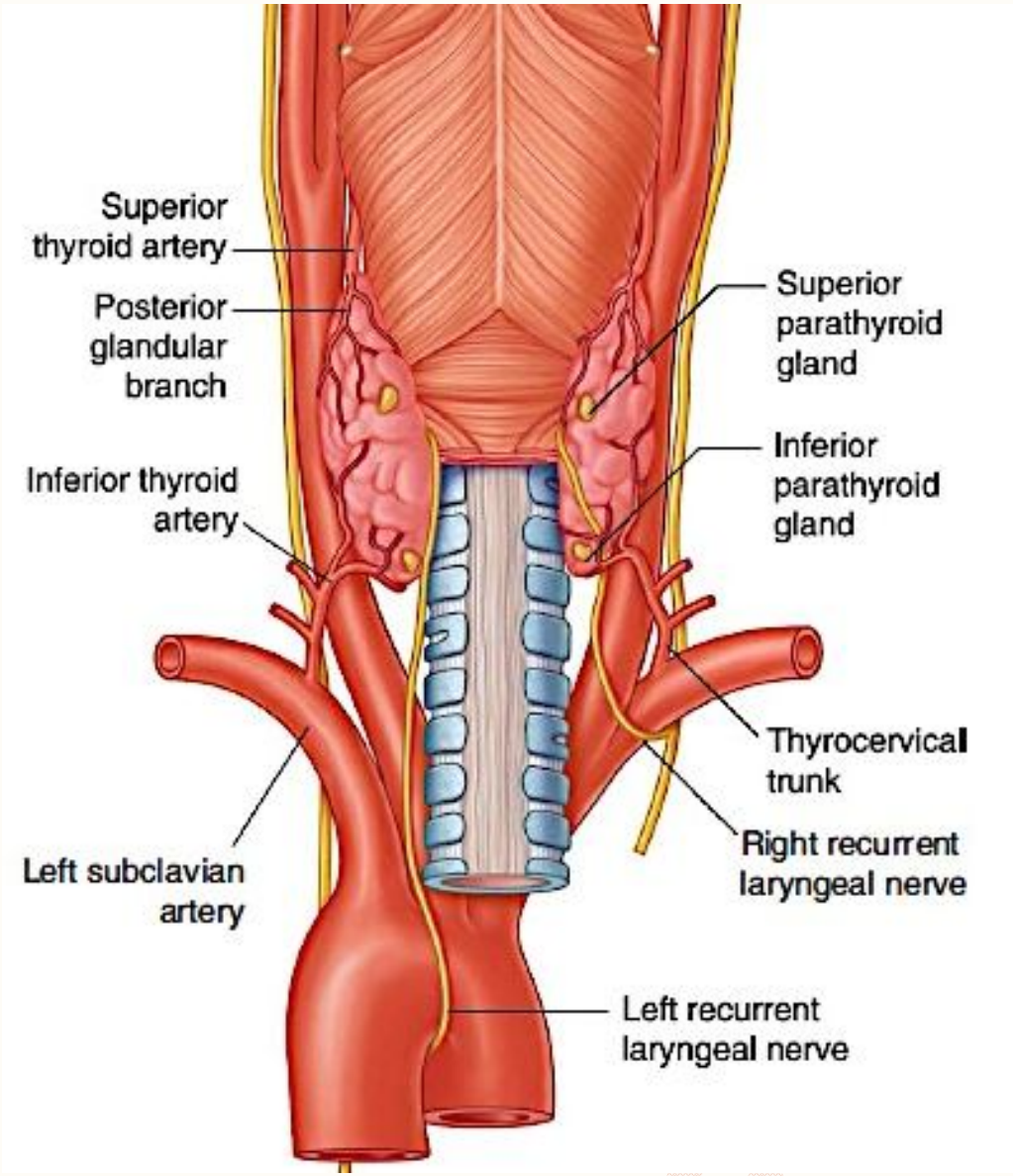

Third Pharyngeal Pouch

The 3rd and 4th pouches are characterized by a dorsal and a ventral wing

In the 5th week, epithelium of the dorsal wing of the third pouch differentiates into the **inferior parathyroid gland,** while the ventral wing forms the **thymus**

Epithelium of the dorsal region of the 4th pharyngeal pouch forms the **superior parathyroid gland**

lose their connection with the pharyngeal wall

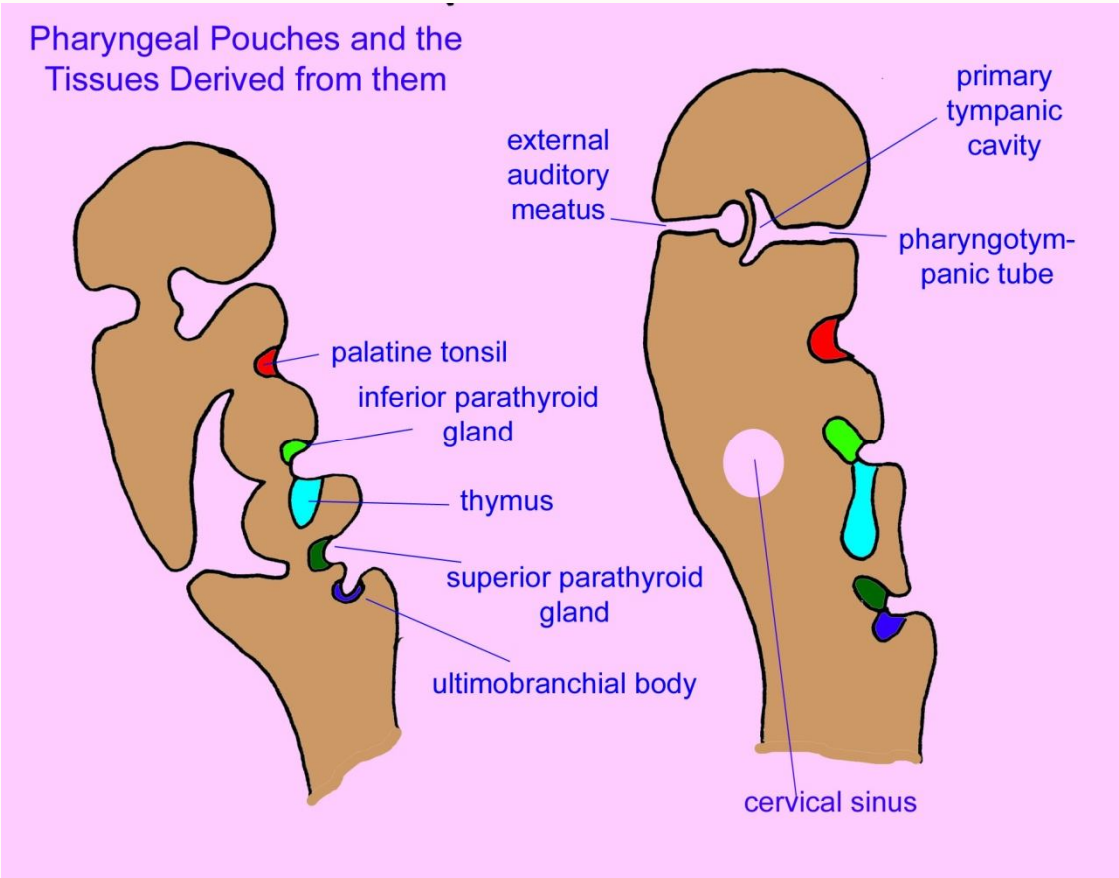

the thymus then migrates in a caudal and a medial direction, pulling the **inferior parathyroid** with it

The parathyroid tissue of the 3rd and 4th pouch finally comes to rest on the dorsal surface of the thyroid gland and forms the **parathyroid glands**

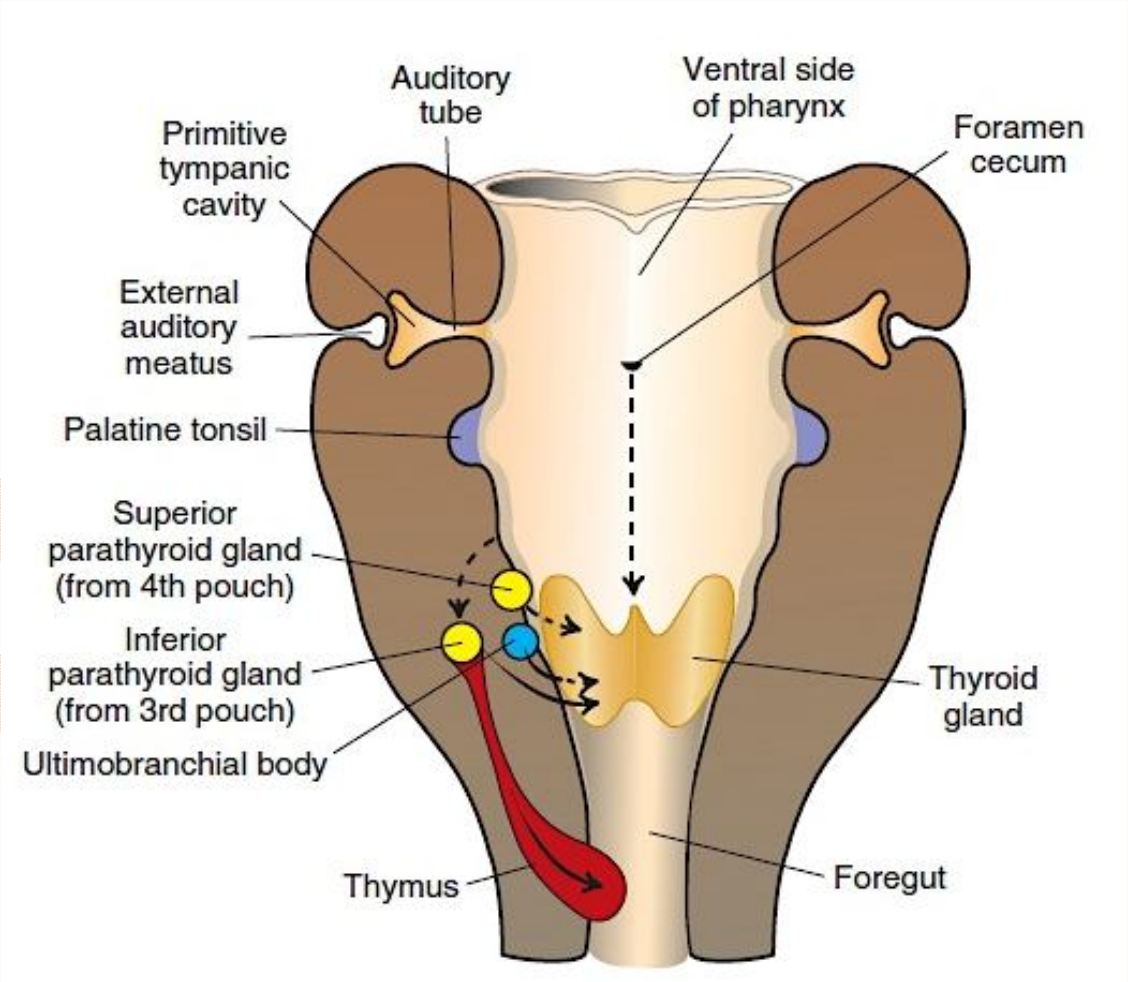

the epithelial cells of the parathyroid gland

- ***Principal (chief) cells:***
- the more numerous of the parenchymal cells of the parathyroid
- responsible for regulating the synthesis, storage, and secretion of large amounts of PTH. small, polygonal cells, with a diameter of 7 to 10 μm
- nucleus located centrally
- The pale-staining
- slightly acidophilic cytoplasm contains lipofuscin-containing vesicles
- large accumulations of glycogen, and lipid droplets

- ***Oxyphil cells :***
- constitute a minor portion of the parenchymal cells
- not known to have a secretory role
- They are found singly or in clusters
- the cells are more rounded, considerably larger than the principal cells
- have a distinctly acidophilic cytoplasm
- Abundant Mitochondria / responsible for the strong acidophilic of these cells
- No secretory vesicles

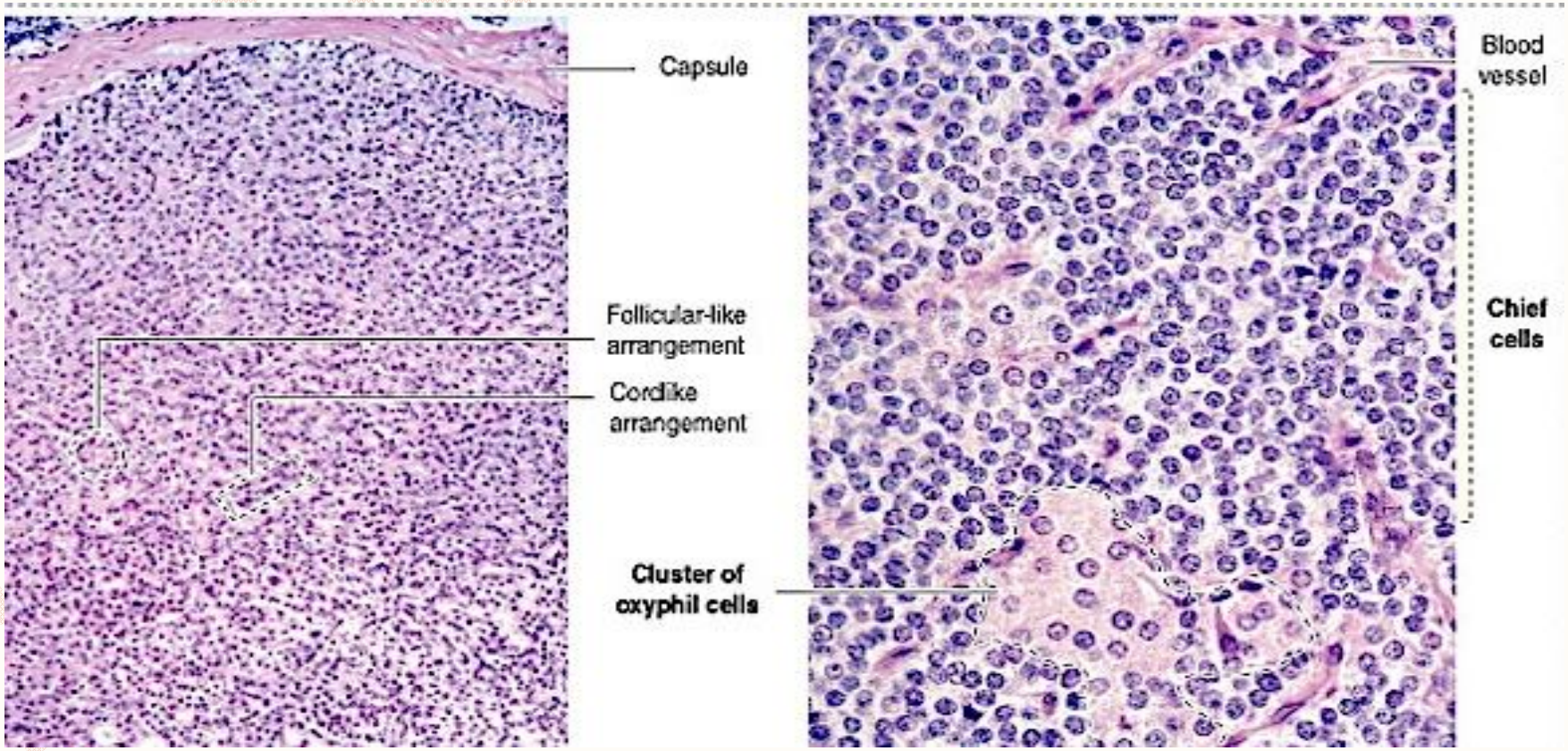
Capsule
Follicular-like arrangement
Cordlike arrangement
Cluster of oxyphil cells
Blood vessel
Chief cells

Structure and function of the parathyroid gland

PTH increase Ca^{+} in blood by 2 ways:

1. Absorb Ca^{+} from distal tubule of kidney & intestine
2. Activate osteoclast cell function

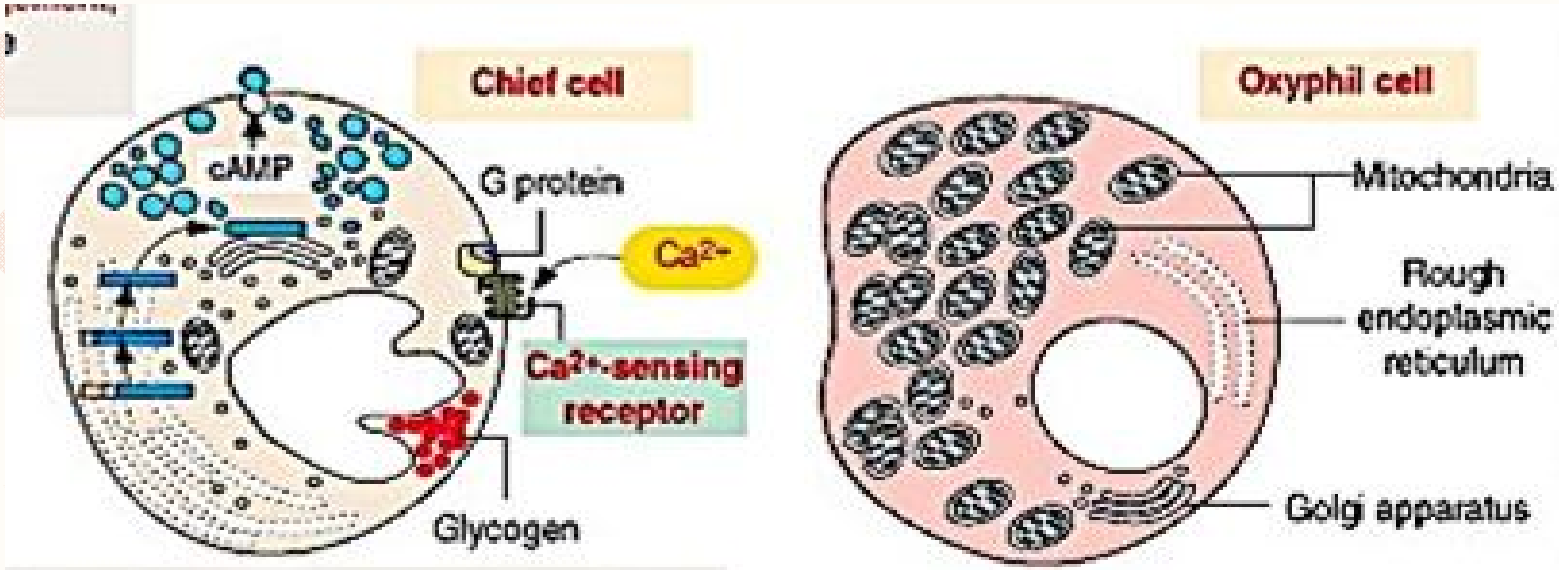

Chief cells synthesize and secrete PTH. Ca^{2+}-sensing receptor (CaSR) is a seven-transmembrane-spanning receptor coupled to G protein on the plasma membrane of the parathyroid cell. A **reduction** in serum calcium levels activates CaSR and **increases PTH secretion**, with a resultant **increase** in serum calcium.

Oxyphil cells appear after puberty and increase in number with age. They contain abundant **mitochondria**, which give this cell type an acidophilic staining in hematoxylin-eosin preparations. The rough endoplasmic reticulum and Golgi apparatus are not prominent. Oxyphil cells do not secrete PTH.

Parathyroid hormone regulates osteoclastogenesis

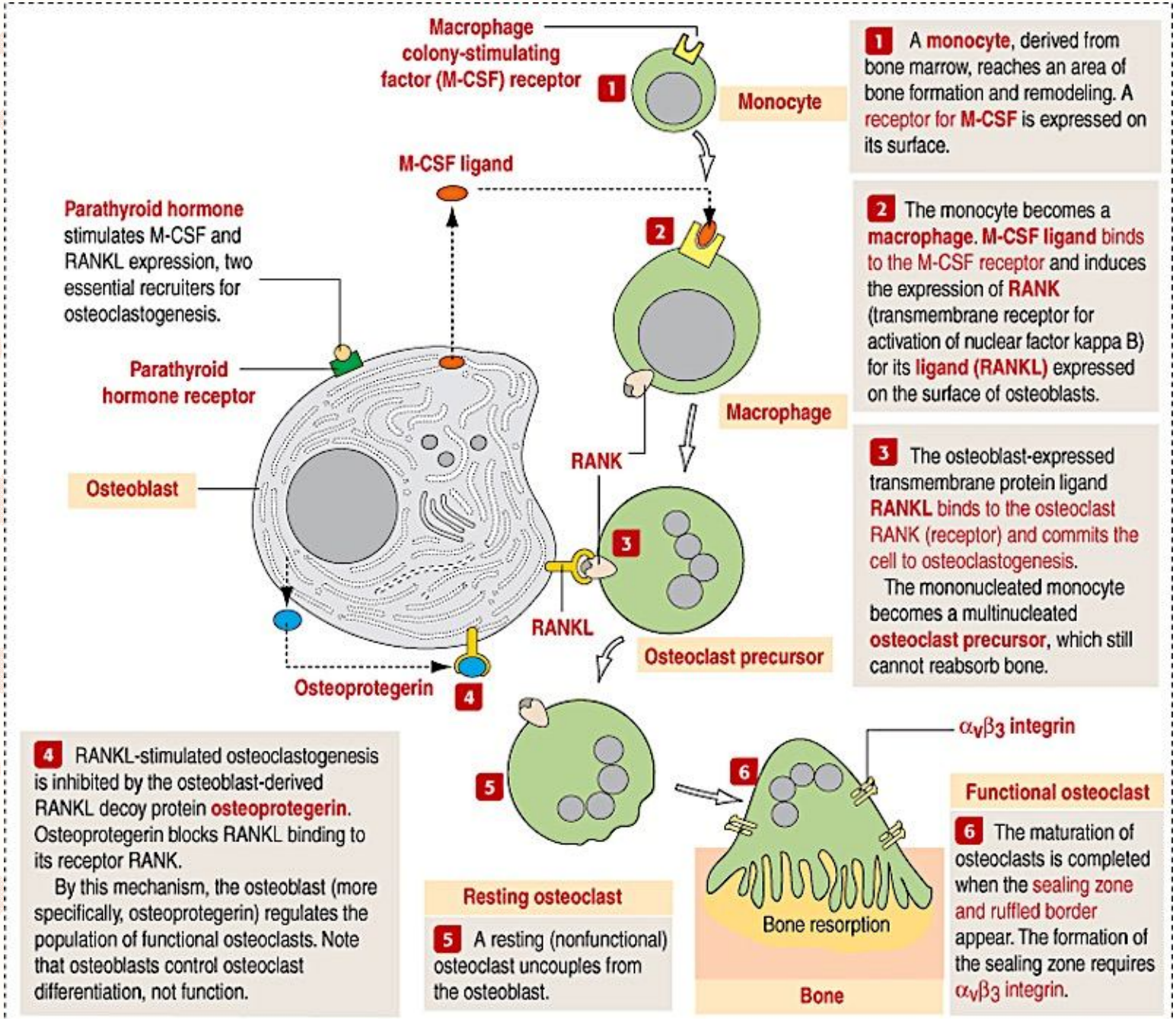

CLINICAL CORRELATION

Parathyroid Glands

1. The variations in position of parathyroid glands described above are of considerable importance to a surgeon trying to locate the glands.
2. The parathyroid glands can be seen when the thyroid is imaged using radioactive iodine. The areas where radioactive materials are located can be recorded on a gamma camera. Computer separation of images reveals the location of the parathyroids.

Hyperparathyroidism

3. Excessive amounts of circulating parathormone can be present in tumours of the parathyroid gland (*parathyroid adenoma*).
   a. As a result calcium is depleted from bones that become weak (and can fracture).
   b. Increased urinary excretion of calcium may lead to formation of urinary calculi.

Hypoparathyroidism

4. Calcium levels in blood fall leading to muscular irritability and convulsions. The condition may be spontaneous or may occur following accidental removal of parathyroid glands during thyroidectomy.

Neuro endocrine
&
Endocrine

Hypophysis gland

Pineal body

Pancreatic islets

Thyroid gland

Parathyroid gland

Suprarenal gland

Suprarenal glands

- Located on superior pole of kidney
- Cover by renal fascia
- a thin septum separates each gland from its associated kidney
- Rt. Adrenal gland = pyramid shape
- Lt. adrenal gland = arcuat shape
- Consist of =
- Cortex = yellow
- Medulla = brown

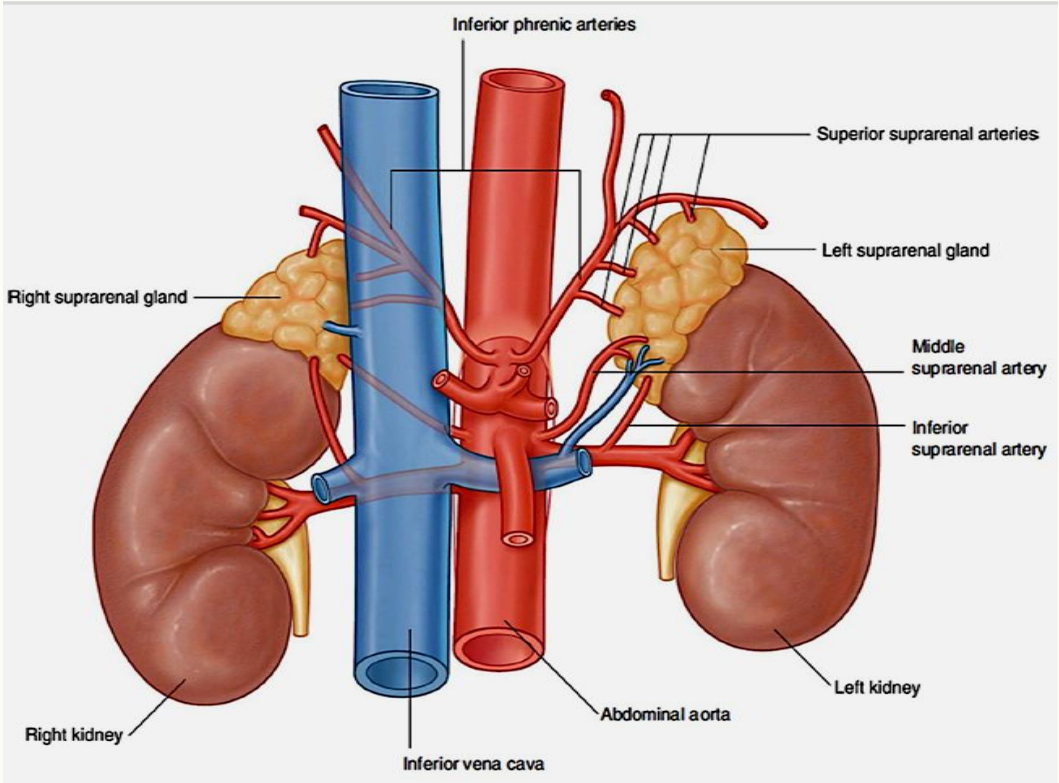

Anterior to the right suprarenal gland is

right lobe of the liver
the inferior vena cava (IVC)

Anterior to the left suprarenal gland is

Stomach
Pancreas
spleen

posterior to both glands:

Parts of the diaphragm

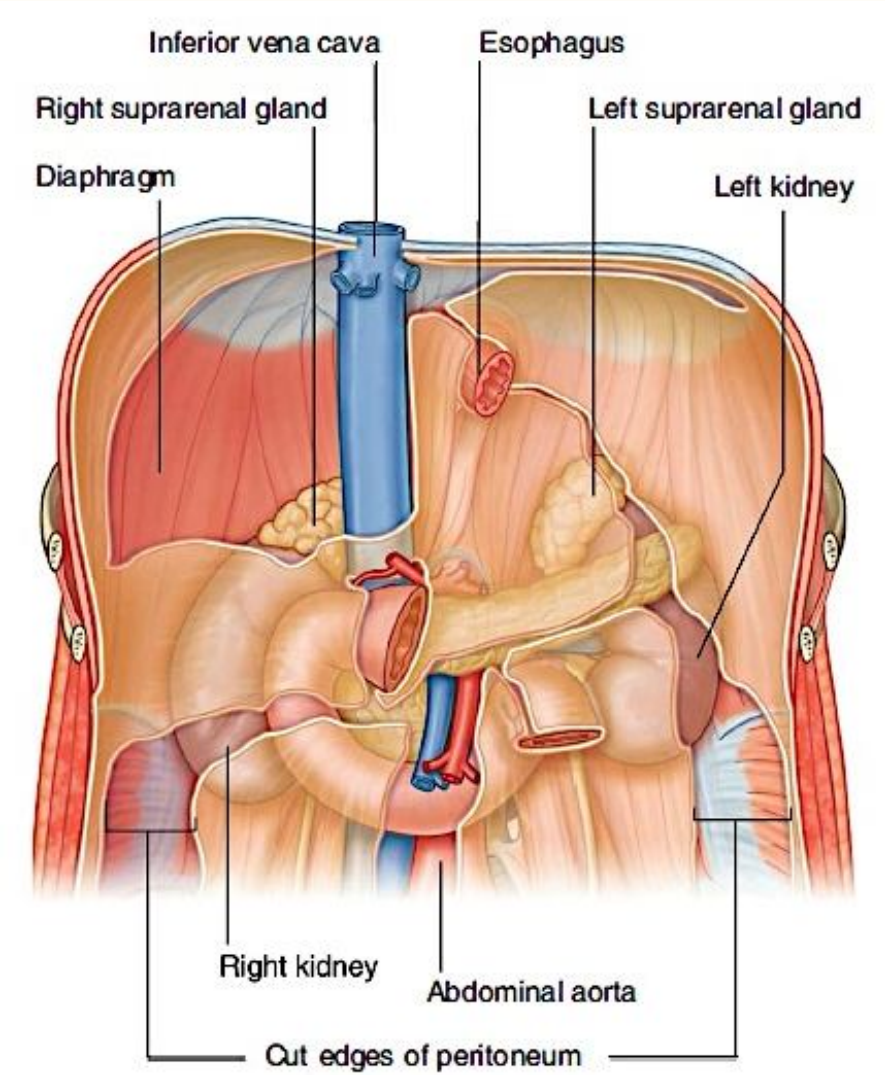

Fig. 4.137 Retroperitoneal position of the kidneys in the posterior abdominal region.

Suprarenal vasculature

arises from ***three*** primary sources:

- As the bilateral ***inferior phrenic arteries*** pass upward from the abdominal aorta to the diaphragm, they give off multiple branches (***superior suprarenal arteries***) to the suprarenal glands.

- A middle branch (***middle suprarenal artery***) to the suprarenal glands usually arises directly from the ***abdominal aorta***.

- Inferior branches (***inferior suprarenal arteries***) from the ***renal arteries*** pass upward to the suprarenal glands

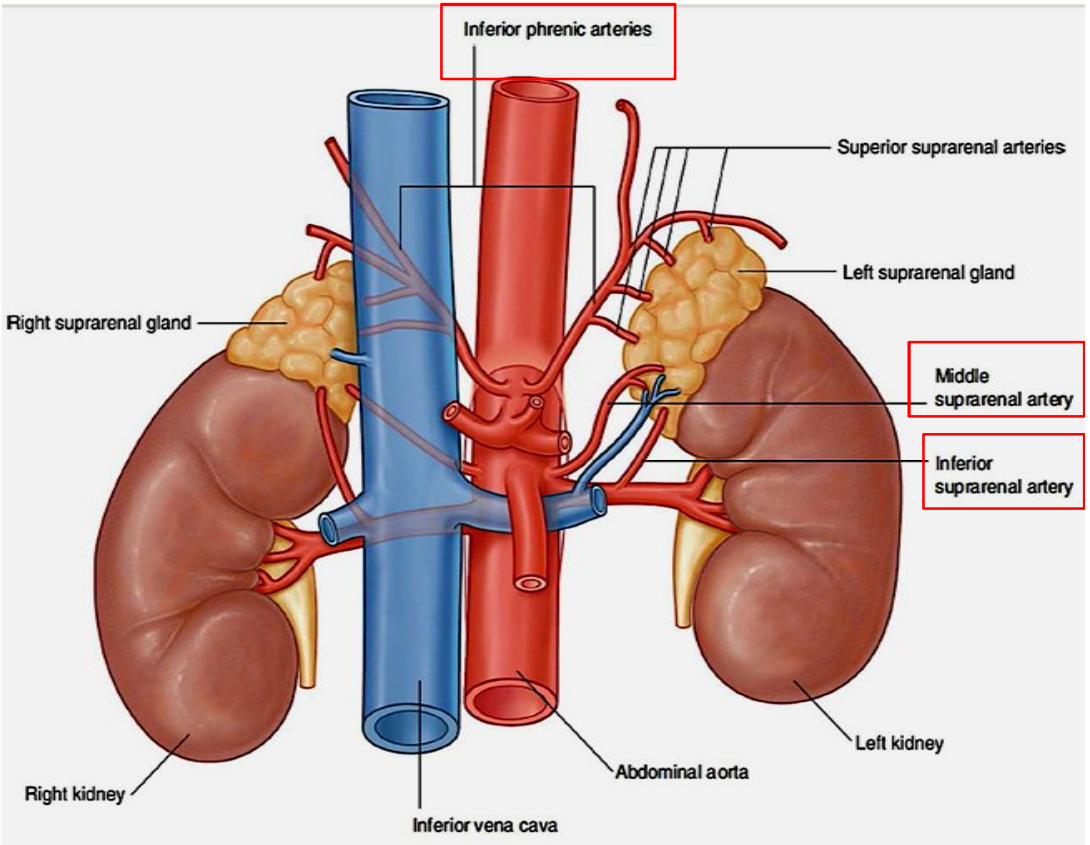

the ***venous drainage***, which usually consists of a ***single vein leaving the hilum of each gland***. ***the right suprarenal vein*** is short and almost immediately enters the **inferior vena cava** ***the left suprarenal vein*** passes inferiorly to enter the ***left renal vein***

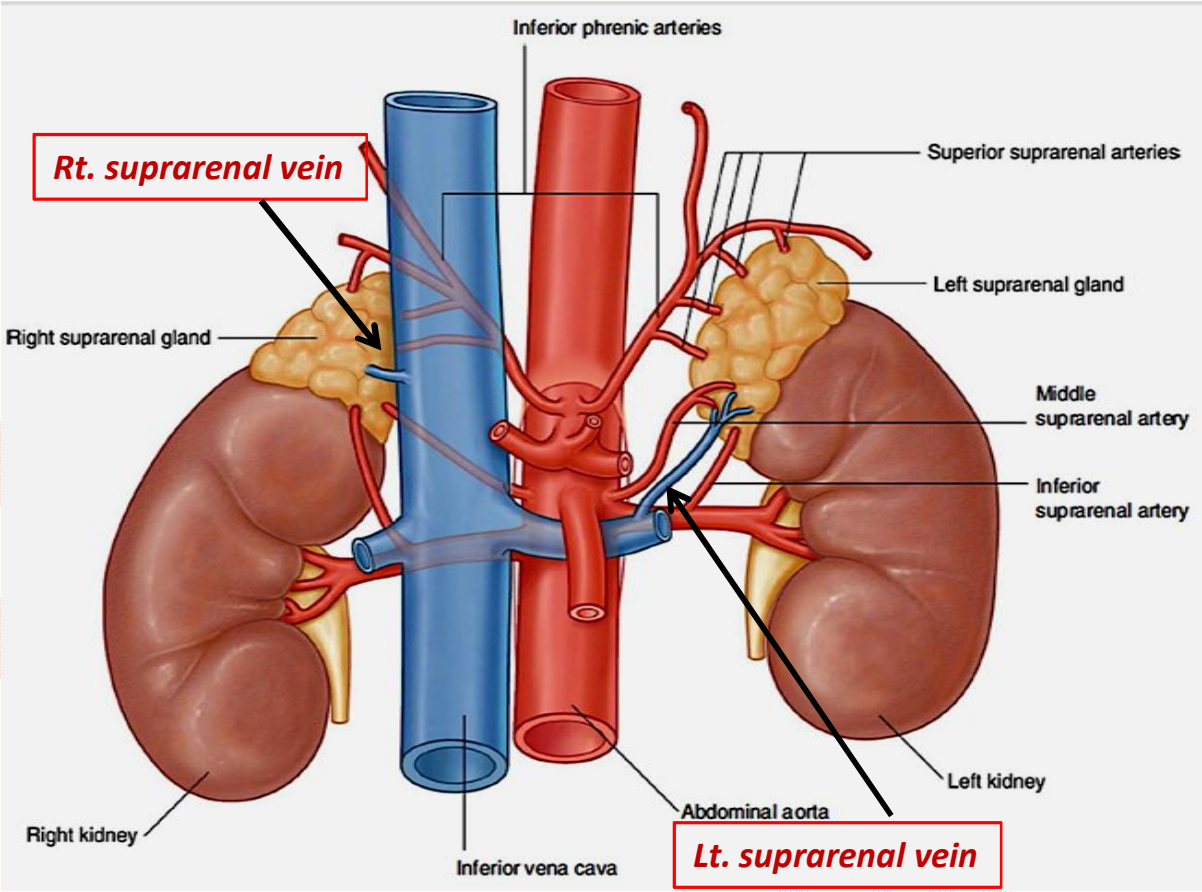

Suprarenal Gland

The suprarenal gland develops from two components:

(1) a mesodermal portion, which forms the **cortex**
(2) an ectodermal portion, which forms the **medulla**

During the ***fifth week*** of development, ***mesothelial cells between the root of the mesentery*** and the ***developing gonad*** begin to proliferate and ***penetrate the underlying mesenchyme***

differentiate into large acidophilic organs, which form the ***fetal cortex***, or **primitive cortex**

a second wave of cells from the mesothelium penetrates the mesenchyme and ***surrounds the original acidophilic cell mass***

form the ***definitive cortex*** of the gland

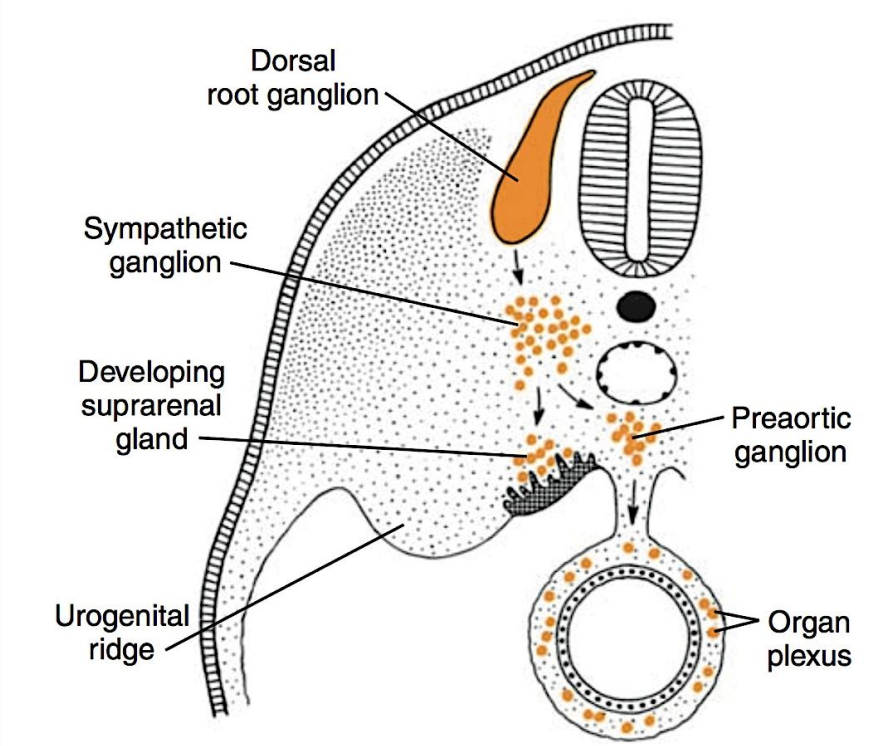

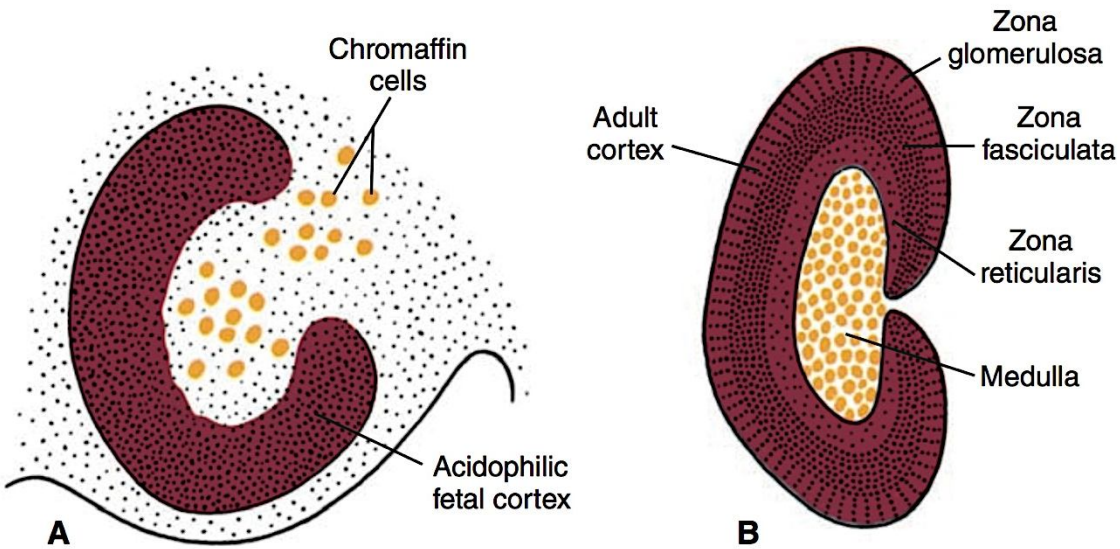

After birth, the fetal cortex regresses rapidly except for its outermost layer, which differentiates into the reticular zone

(the remaining definitive cortical cells then organize into the zona glomerulosa, zona fasciculata, and zona reticularis layers seen in the adult suprarenal gland)

- The adult structure of the cortex is not achieved until puberty.

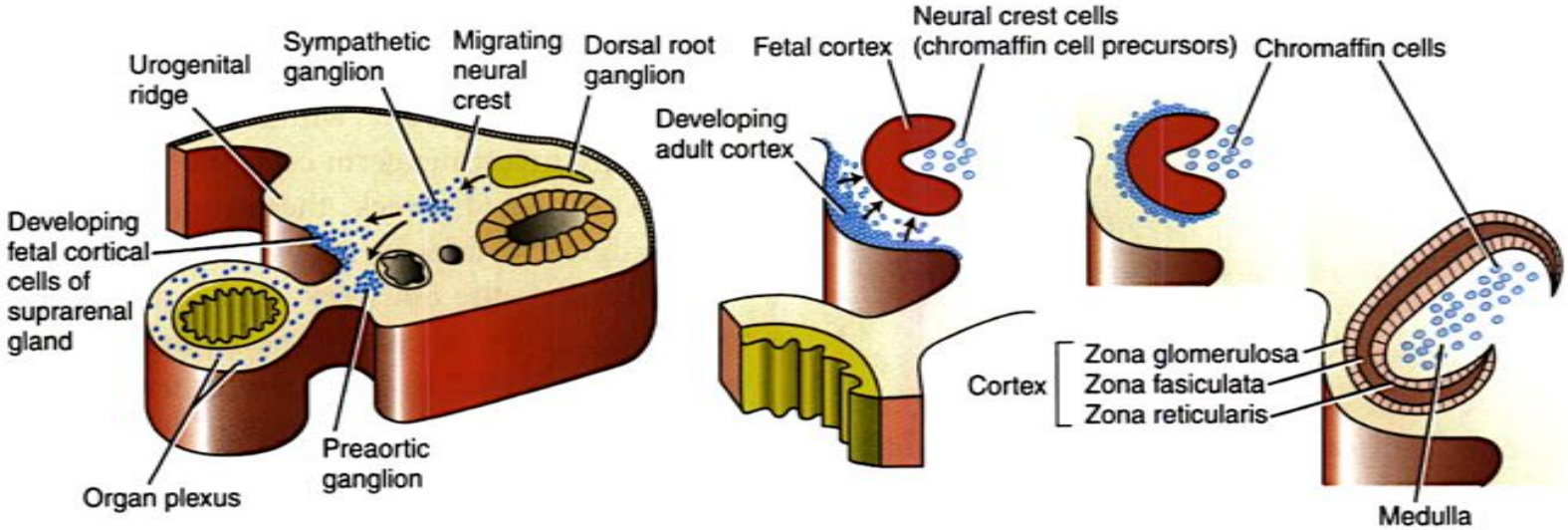

Figure 15-15. Suprarenal gland development. During the 5th week of development, the coelomic epithelium adjacent the developing gonadal ridge proliferates and a subset of cells delaminate and enter the underlying mesoderm, forming the fetal suprarenal cortical cells. A second wave of delaminating cells migrates and forms a thinner definitive cortex surrounding the fetal cortex. By the 2nd postnatal month, the fetal cortex rapidly regresses and the remaining definitive cortical cells organize into the zona glomerulosa, zona fasciculata, and zona reticularis layers seen in the adult suprarenal gland. Before being cordoned off by the forming suprarenal capsule, neural crest cells migrate into the medullary region and differentiate into chromaffin cells.

neural crest cells invade its medial aspect, where they are arranged in cords and clusters give rise to the medulla of the suprarenal gland

- They stain yellow-brown with chrome salts and hence are called ***chromaffin cells***
- innervated by preganglionic sympathetic fibers that release *Epinephrine* and *Norepinephrine* upon sympathetic stimulation.

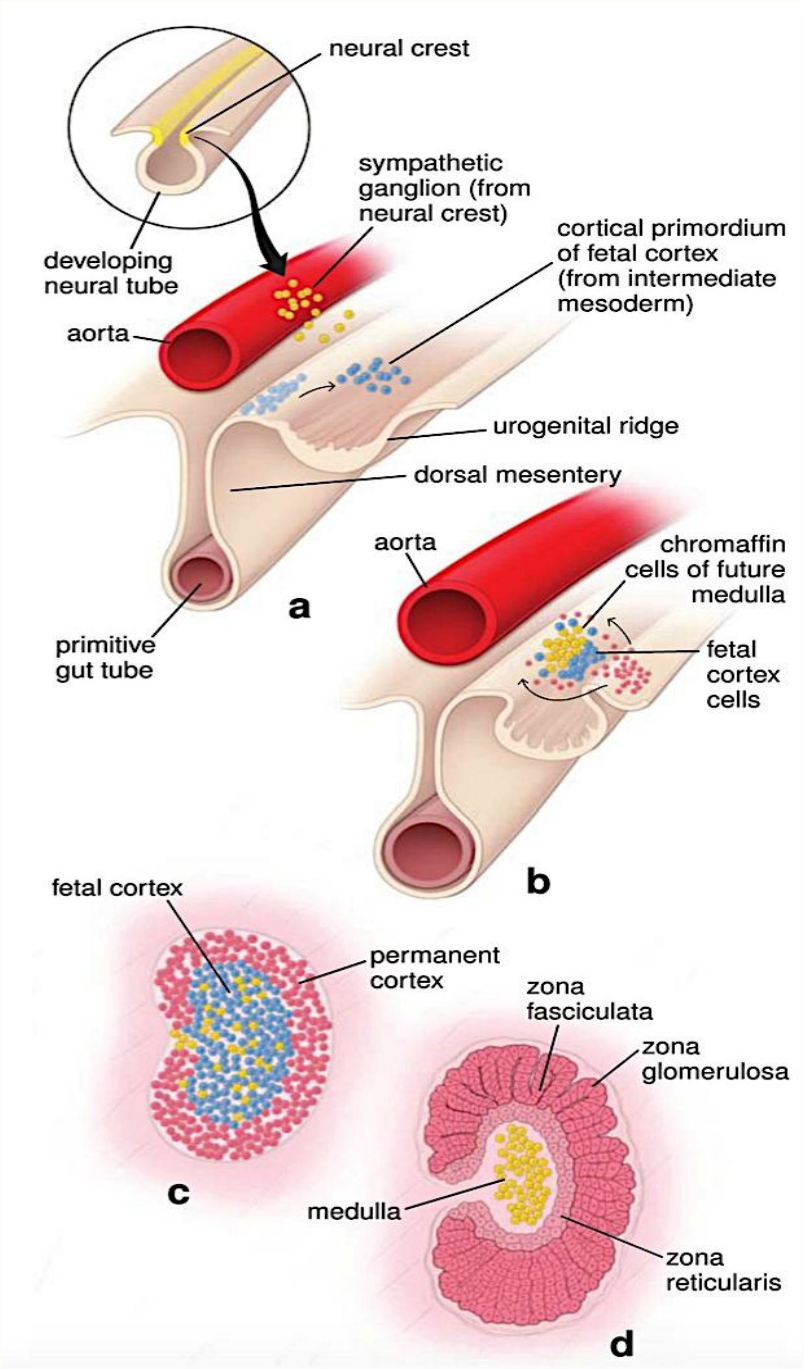

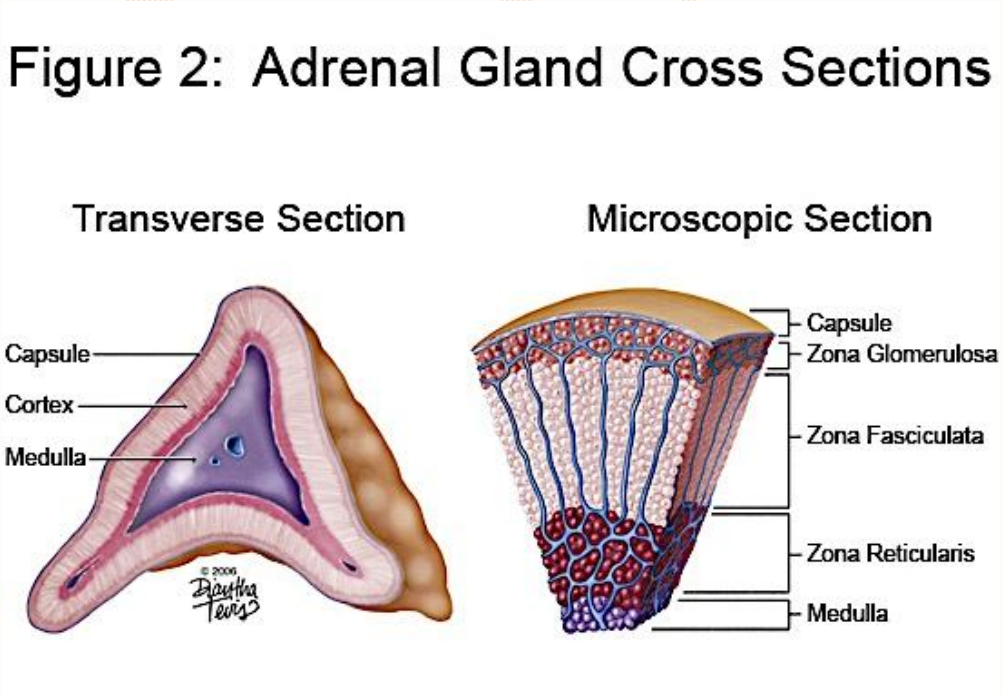

Suprarenal gland:

- ***Cortex = 80-90%***

Zona glomerulosa
Zona fasciculata
Zona reticularis

- ***medulla***

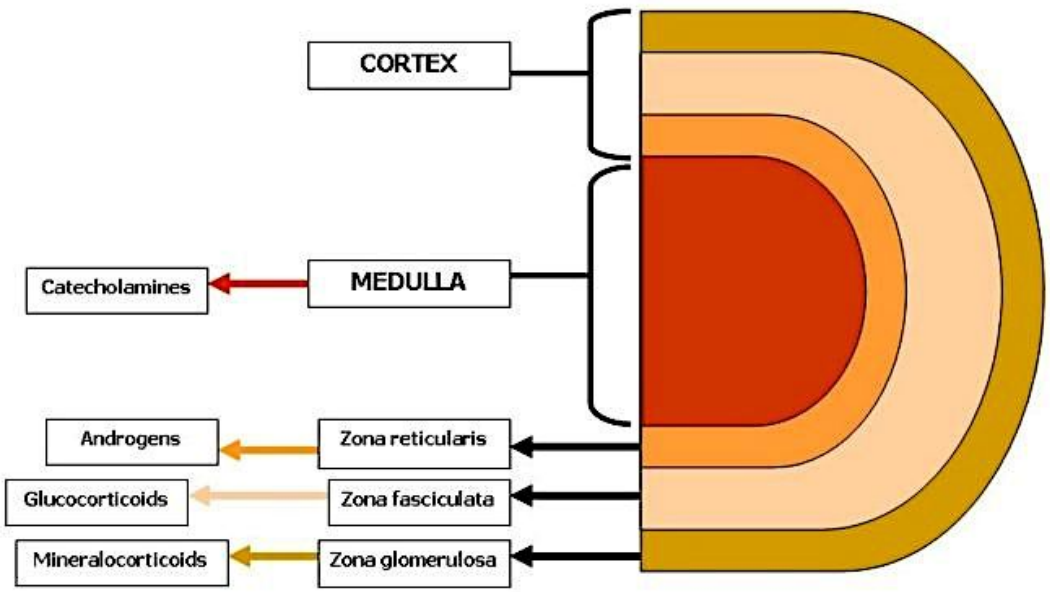

Zona glomerulosa :

15% of total volume
Pyramidal cell
Formation of round / arcuate mass
Surrounded by fenestrated vessels

Ultra structure:

SER
Many mitochondria

Secretion of mineral corticoids hormones
(aldosterone) : functions

Water / electrolyte balance
Na / water reabsorption
from
distal tubule & gastric mucosa & sweat glands & salivary glands

Stimulator :

Angiotensinogen II / ACTH

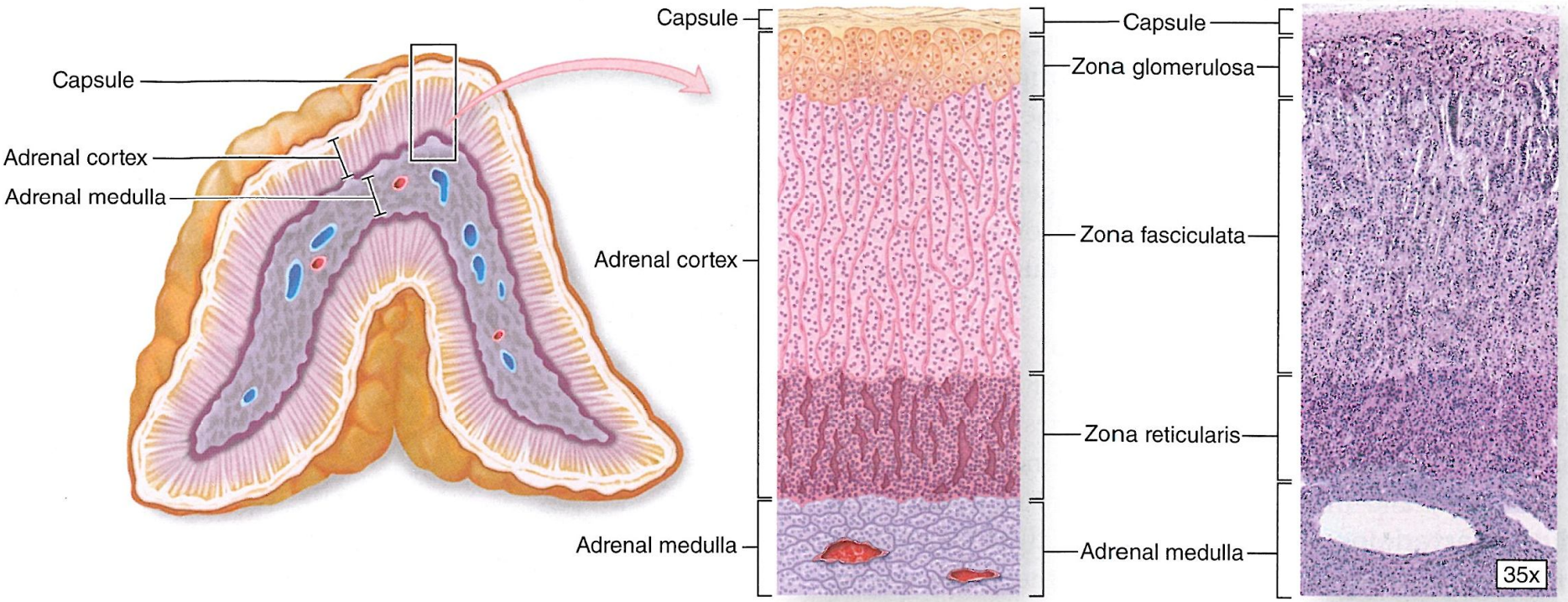
Capsule
Adrenal cortex
Adrenal medulla
Capsule
Adrenal cortex
Adrenal medulla
Capsule
Zona glomerulosa
Zona fasciculata
Zona reticularis
Adrenal medulla
35x

Zona fasciculata :

50% of total volume
Cells form cord mass
Surrounded by fenestrated vessels

Ultra structure:

SER
Many mitochondria
Spongiocyte (lipid droplet) in cytoplasm

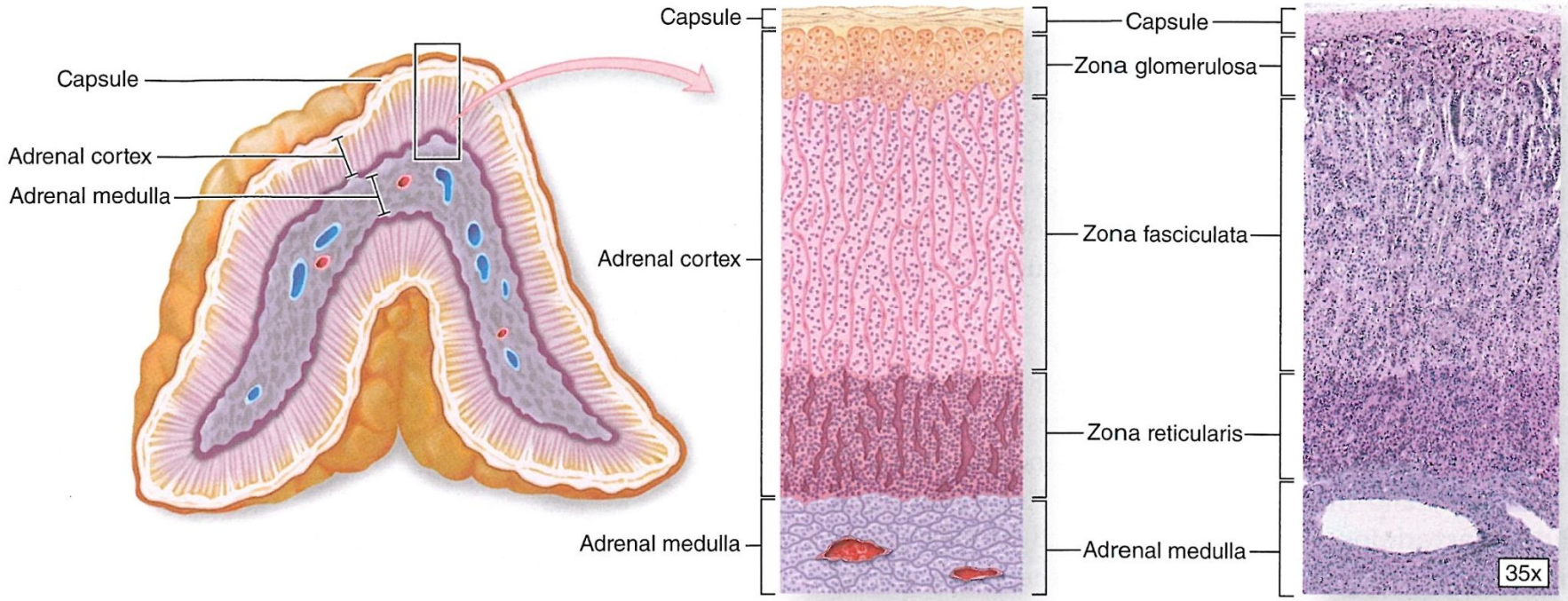

Secretion :

glucocorticoids hormones

- ***(cortisol / corticostrone) : functions***

In the liver / anabolic:

Glucose synthesis = ↑ BS
Amino acid absorption
↑ fatty acid absorption

Out of the liver / catabolism :

Protein
Fatty acid

- ***Androgen (dehydroepiandrosterone)***

Stimulator :

ACTH

Cortisone functions:

Anti inflammation
Destroy of lymphocytes in circulation
Suppress mitotic activity in lymphoid organ

Adverse effects of Crotone:

Suppress of immune system
Adverse effect in structure of Skeletal system
Bleeding of digestive system

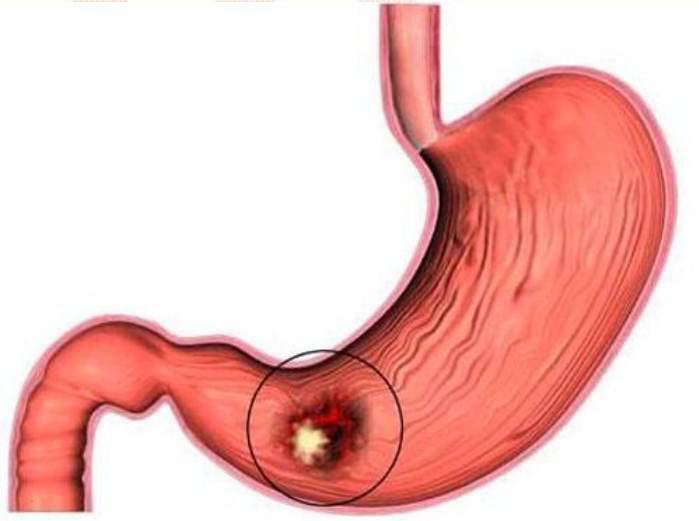

Zona reticularis :

7% of total volume
Cells form irregular pattern
Surrounded by fenestrated vessels

Ultra structure:

SER
Many mitochondria
Pyknotic nucleus
Lipofuscin pigment (more heavily stained)

Secretion:
glucocorticoids / ***Androgen*** hormones

Stimulator :

ACTH

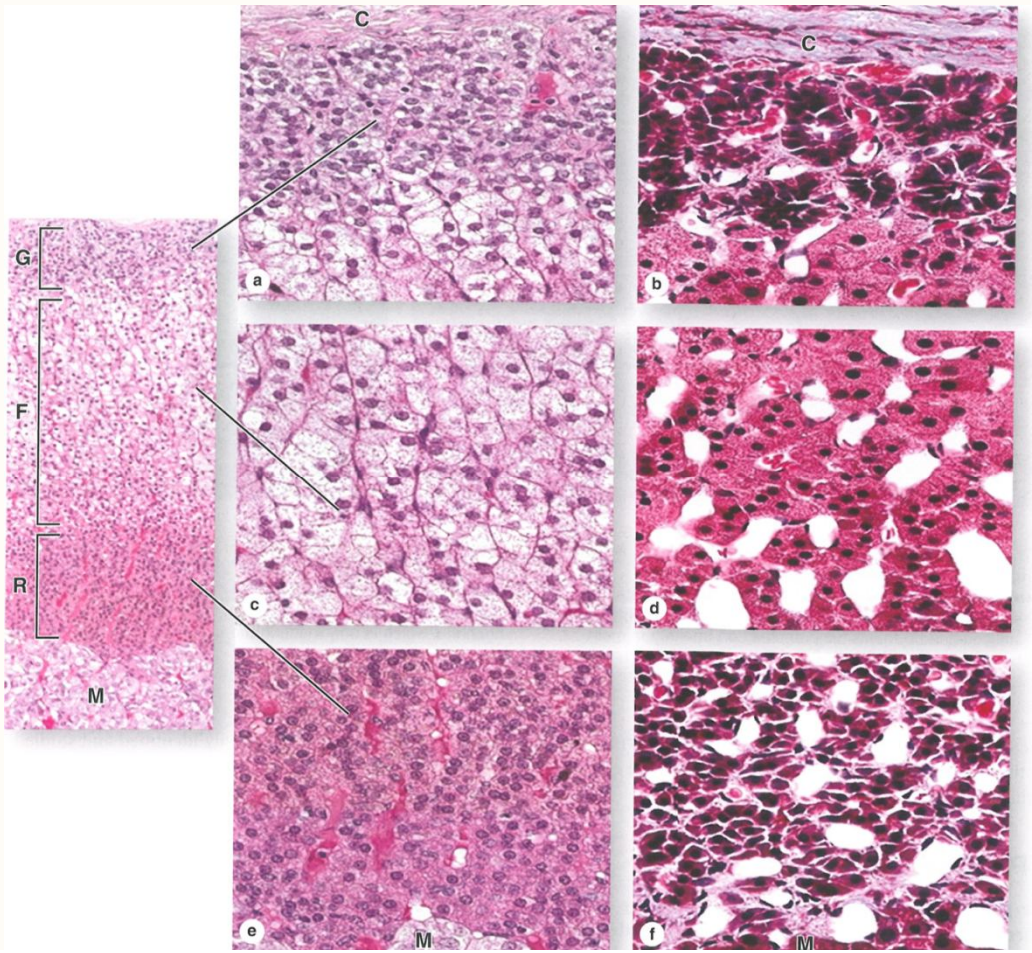

Low hormone secretion of cortex : (Addison's disease)

Autoimmune disease / tuberculosis of adrenal gland
↑ ACTH / skin darkness

MedicineStepByStep.com

Dr J Anthonypillai

Addison's Disease
(Primary Hypoadrenalism)

↓

1. Adrenal Gland
   - Outer Cortex
     - Produces Steroids:
       - Cortisol
       - Aldosterone
       - Androgen

→ 2. DESTRUCTION OF ENTIRE ADRENAL CORTEX

↓

3. Whats causing this...

a. 90% - destruction of entire adrenal cortex by organ specific autoantibodies

b. Rarer causes - haemorrhage, malignant infiltration, adrenal gland tuberculosis

4. What are the clinical features:

a. Non - Specific Symptoms:
- Lethargy
- Depression
- Anorexia
- Weight Loss

b. What else to look out for:
- Postural Hypotension
- Hyper pigmentation
- Vitiligo
- Loss of body hair in women

c. Addisonian Crisis:
- Vomiting
- Abdominal pain
- Profound weakness
- Hypoglycaemia
- Hypovolaemic Shock

High hormone secretion of cortex : (Cushing's syndrome)

↑ ACTH (hypophysis tumor / Zona fasciculata / Zona reticularis tumor)
Boys = Precocious puberty
Female = hirsutism

Tumor in Zona glomerulosa :

↑ aldosterone
Conn's syndrome

Cause:
Bilateral idiopathic (micronodular) adrenal hyperplasia (66%)
Adrenal adenoma (Conn's syndrome) (33%)

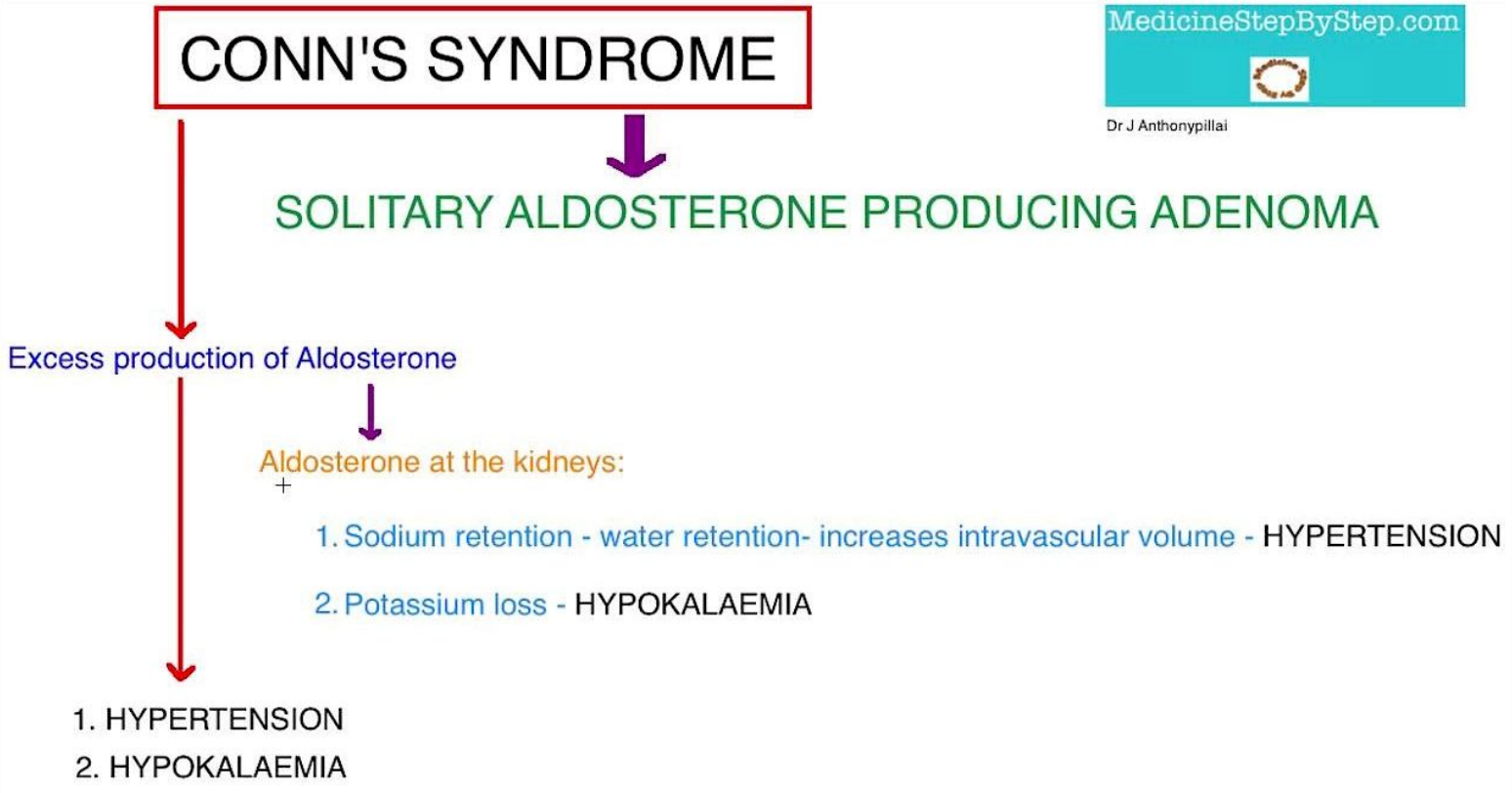

Synthesis of steroids in the adrenal cortex

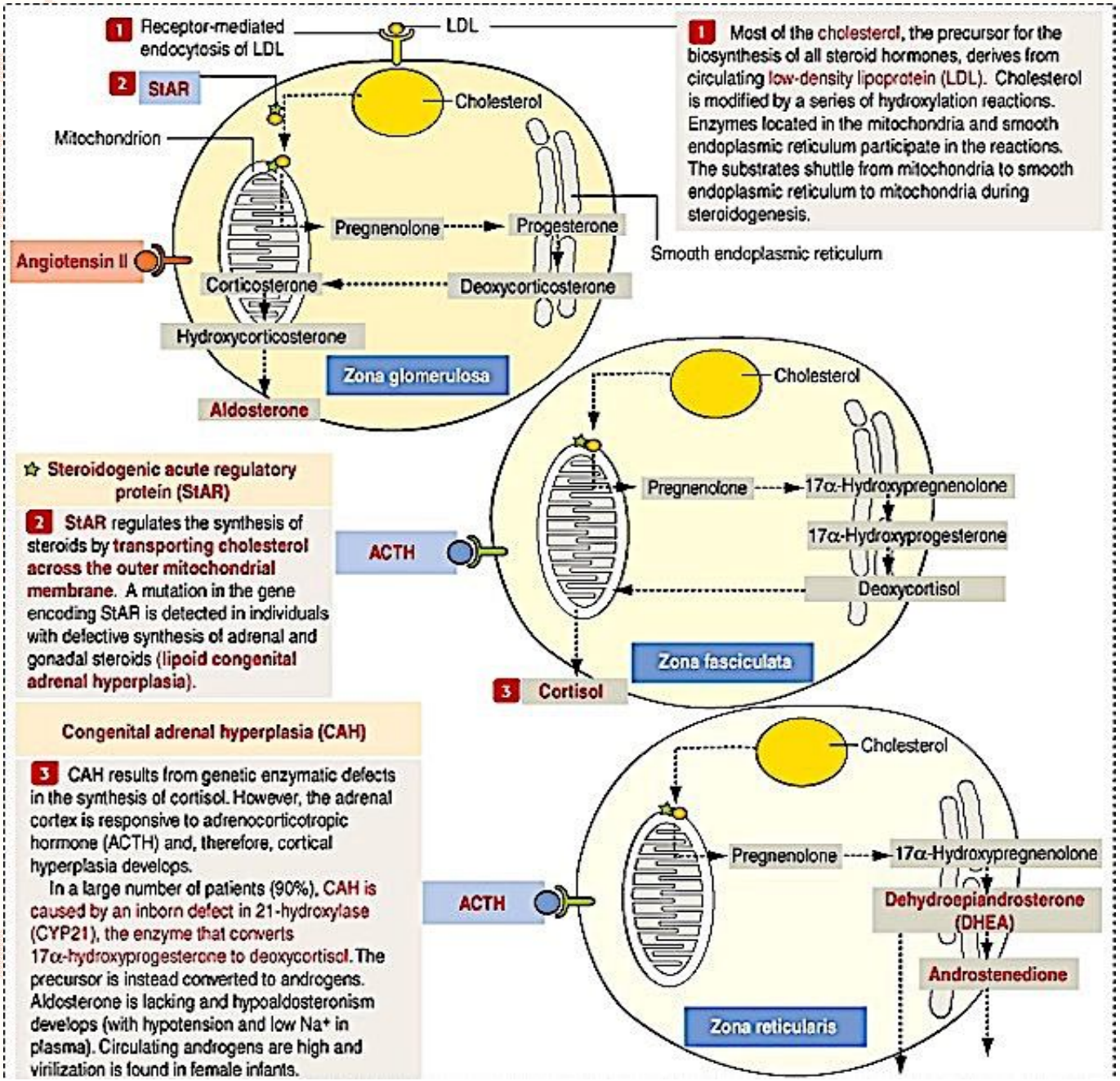

Suprarenal gland:

- ***Cortex = 80-90%***

Zona glomerulosa
Zona fasciculata
Zona reticularis

- ***medulla***

Ultra structure :

Acidophilic cells
Large nucleus
Reticular stromal
Arranged in cord / round mass
Modified postganglionic neuron
Catecholamines secretion / ***stored in granules***
Chromaffin cells / chromaffin reaction

Secretion granules:

ATP / chromogranin (attach to Catecholamines) / enkephalin

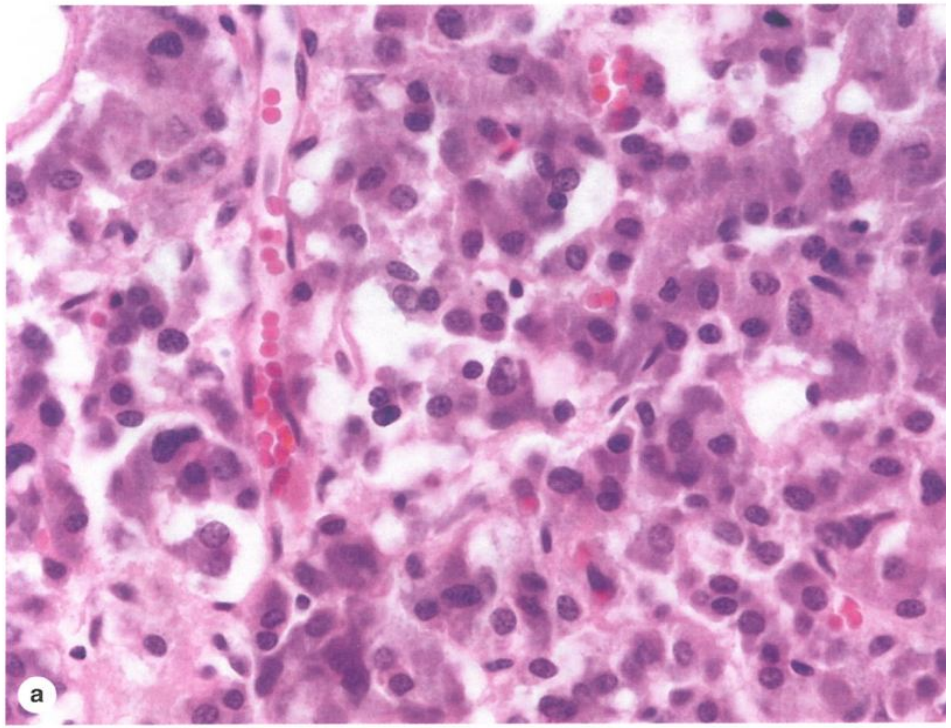

The hormone-secreting cells of the adrenal medulla are chromaffin cells, which resemble sympathetic neurons.
(a) The micrograph shows that they are large pale-staining cells, arranged in cords interspersed with wide capillaries. Faintly stained cytoplasmic granules can be seen in most chromaffin cells. X200. H&E.

Vasoconstriction

↑ BP

↑ HR

↑ BS

Chromaffin cells functions:

Pheochromocytoma

Chromaffin cells tumor
BS / Up
BP / Fluctuation

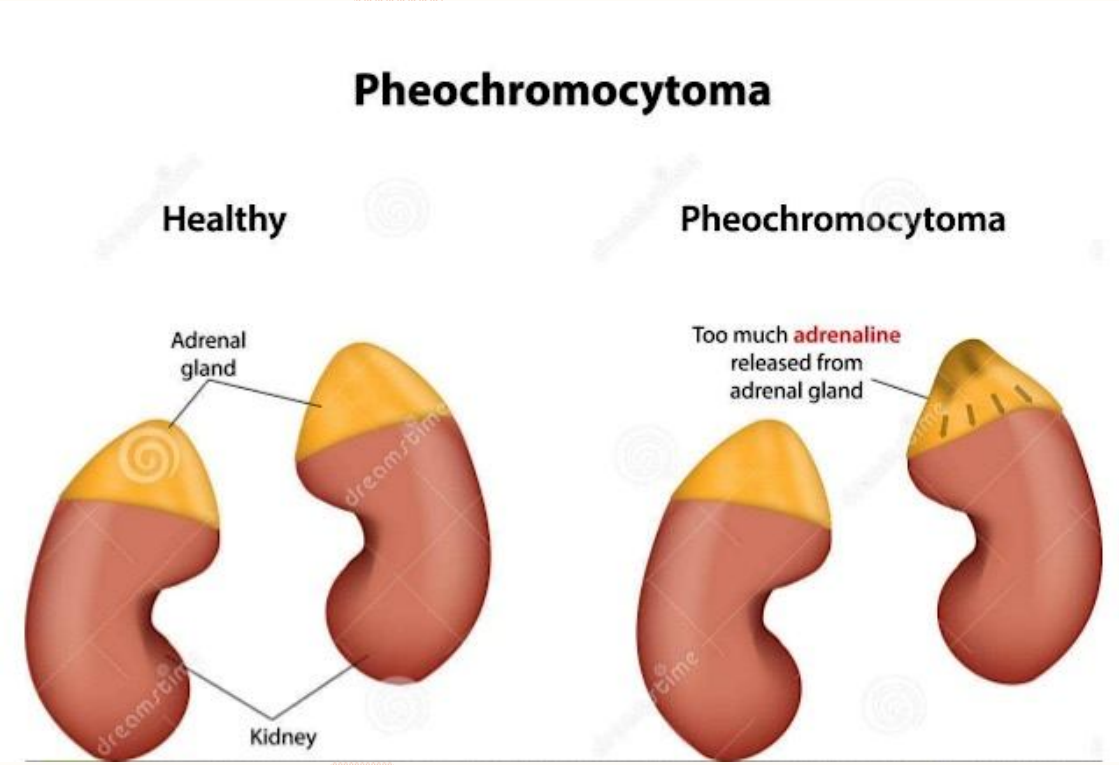

Blood supply to the adrenal gland

Blood vessels derived from the **capsular plexus**, formed by the **superior and middle adrenal arteries**, supply the three zones of the cortex. **Fenestrated cortical capillaries** derive from these blood vessels.

Fenestrated cortical capillaries (also called sinusoids) percolate through the zonae glomerulosa and fasciculata and form a network within the zona reticularis before entering the medulla.

Cortex

Medullary venous sinuses
Mineralocorticoids, cortisol, and sexual steroids enter the medullary venous sinuses.

Central vein

Medulla

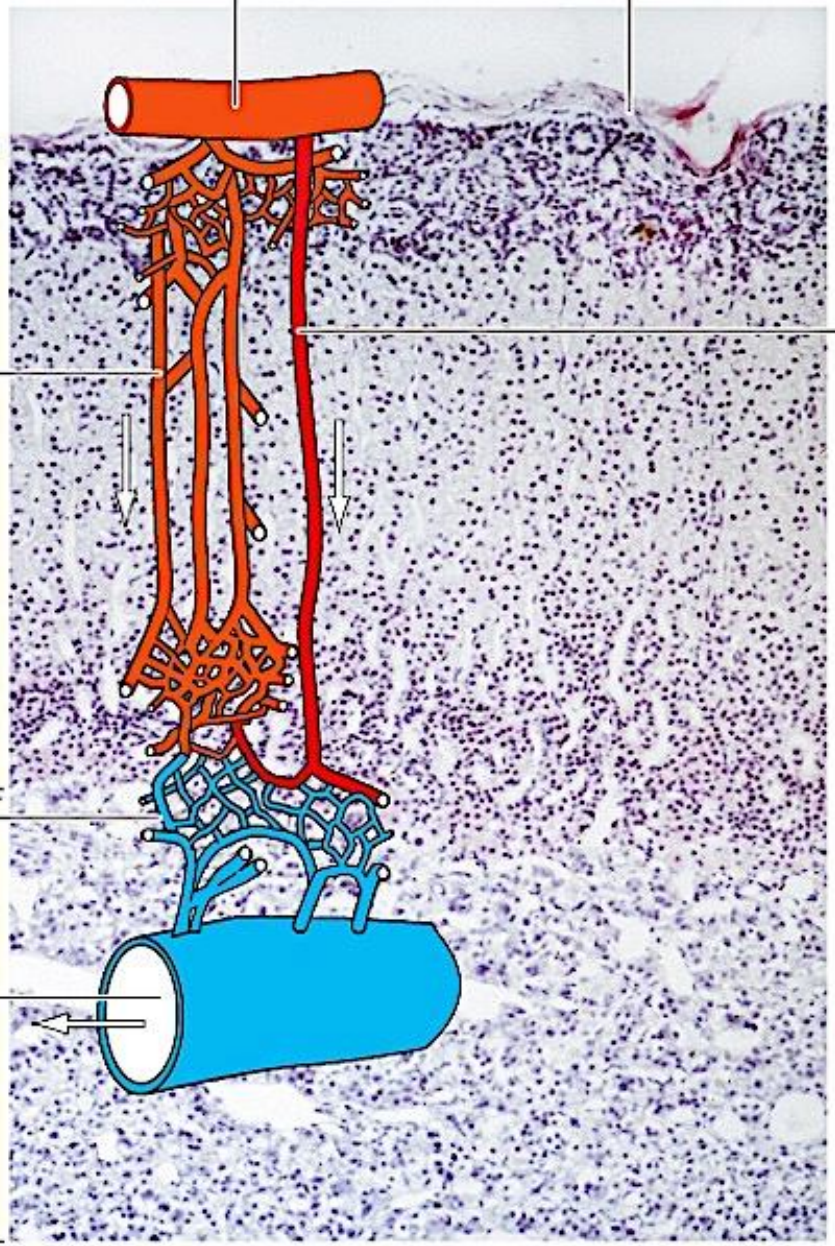

The **medullary artery**, derived from the **inferior adrenal artery**, enters the cortex within a connective tissue trabecula and supplies blood directly to the adrenal medulla.

Medullary artery

The **medullary artery bypasses the cortex without branching**. In the medulla, the artery joins with branches from the cortical capillaries to form **medullary venous sinuses**. Thus, **the medulla has two blood supplies**: one from cortical capillaries and the other from the medullary artery.

The conversion of norepinephrine to epinephrine by chromaffin cells is dependent on **phenylethanolamine *N*-methyltransferase (PNMT)**, an enzyme activated by cortisol transported by the cortical capillaries to the medullary venous sinuses.

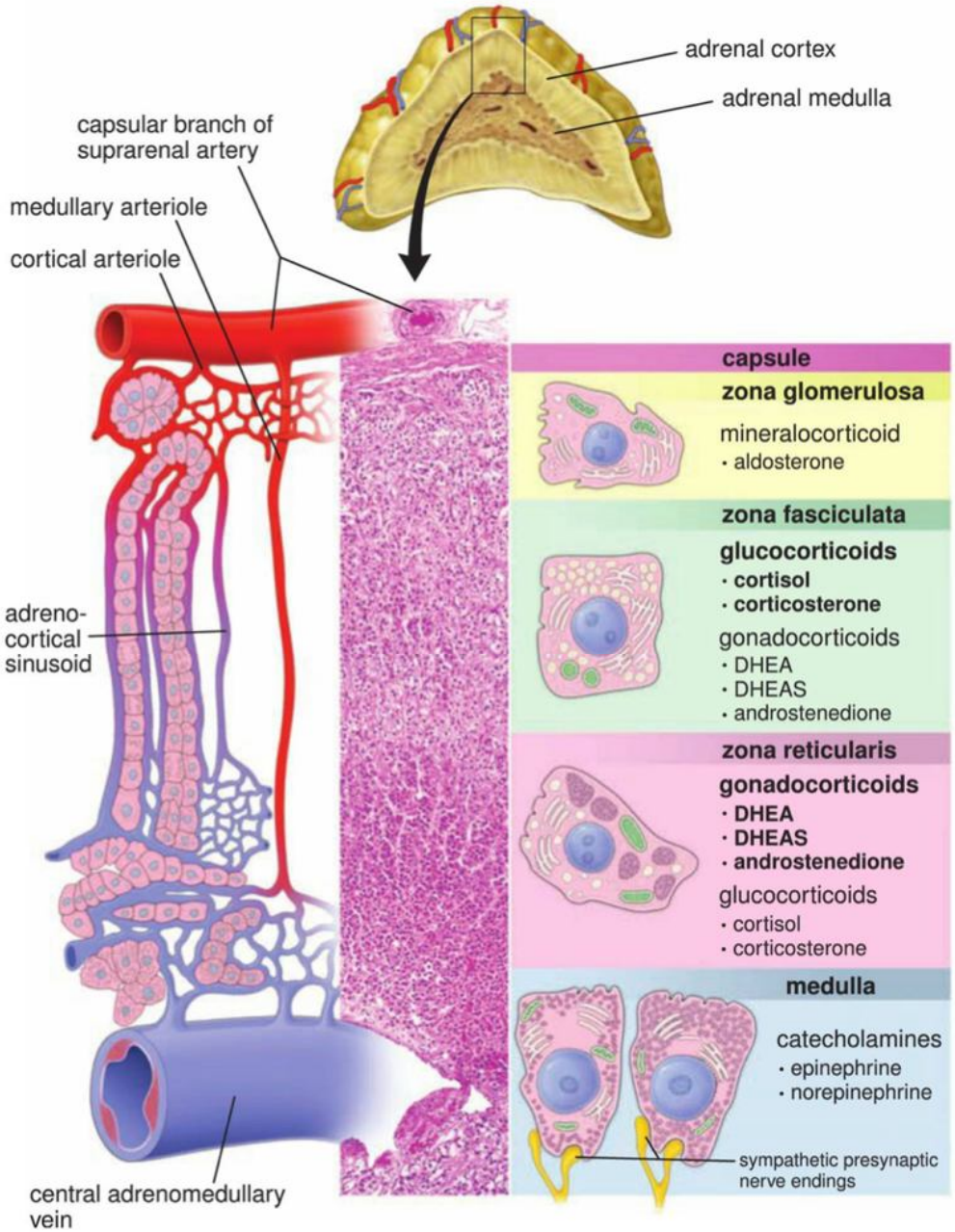

FIGURE 21.23 ▲ Organization and blood supply of the human adrenal gland. This diagram shows the blood supply to the adrenal cortex and medulla. The cortical arterioles form a cortical network of capillaries, which drain into a second capillary network in the medulla. The medullary capillary network is formed primarily by the medullary arterioles and drains into the central medullary vein. Adrenal medulla, zones of the cortex, and features of basic cell types and their secretory products are noted.

Suprarenal vasculature :

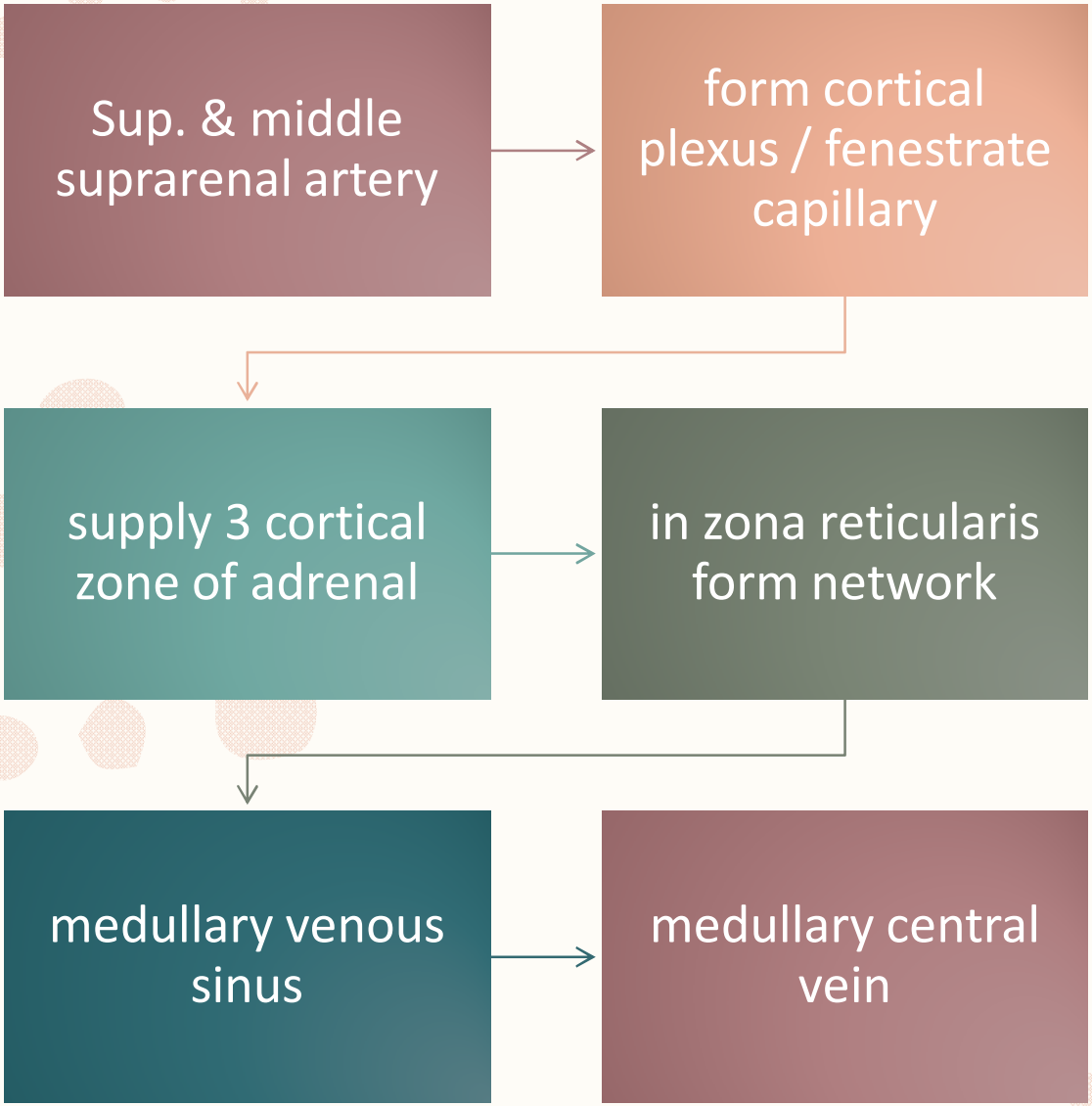

Suprarenal vasculature :

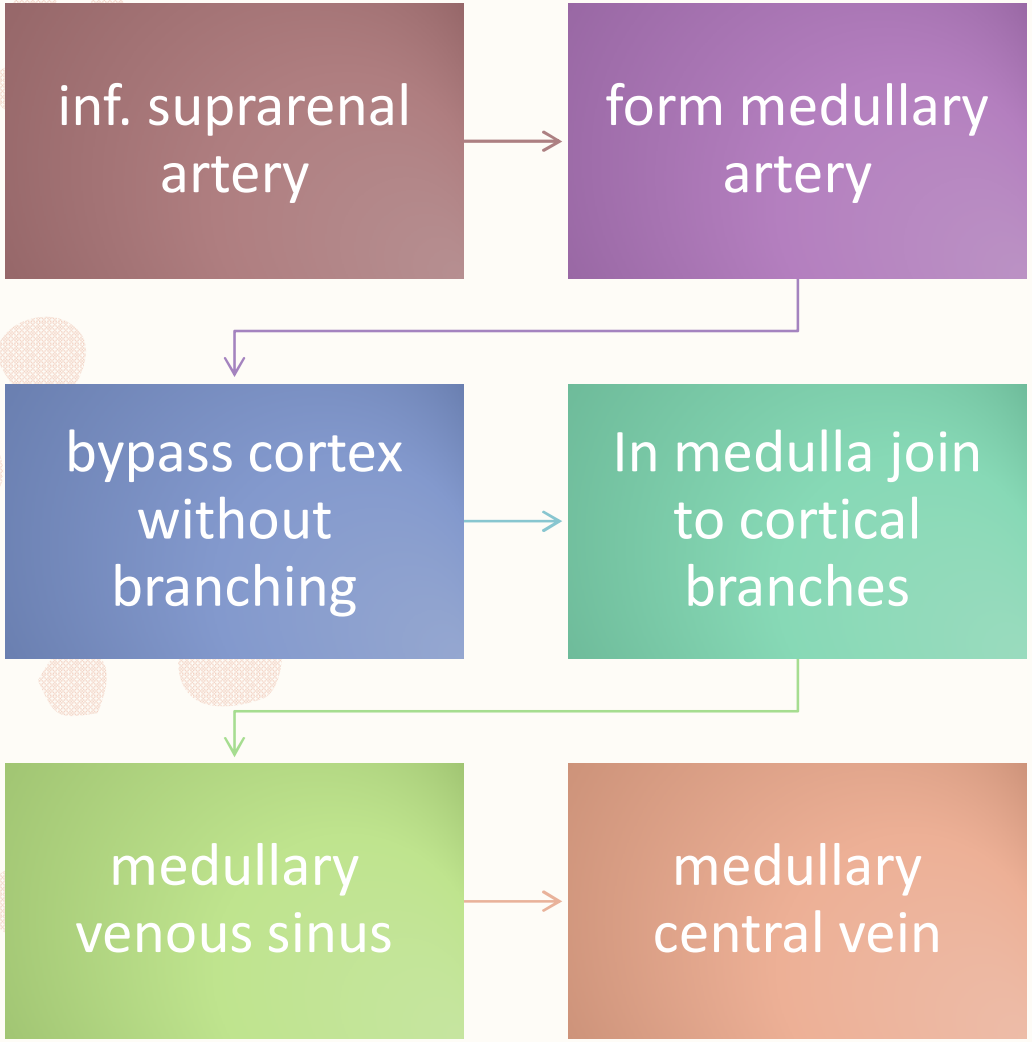

TABLE 20–5 Cells, important hormones, and functions of other major endocrine organs.

Gland	Endocrine Cells	Major Hormones	Major Functions
Adrenal glands: Cortex	Cells of zona glomerulosa	Mineralocorticoids	Stimulate renal reabsorption of water and Na^+ and secretion of K^+ to maintain salt and water balance
	Cells of zona fasciculata	Glucocorticoids	Influence carbohydrate metabolism; suppress immune cell activities
	Cells of zona reticularis	Weak androgens	Precursors for testosterone or estrogen
Adrenal glands: Medulla	Chromaffin cells	Epinephrine	Increases heart rate and constricts vessels
		Norepinephrine	Dilates vessels and increases glucose release
Pancreatic islets	α Cells	Glucagon	Raises blood glucose levels
	β Cells	Insulin	Lowers blood glucose levels
	δ Cells	Somatostatin	Inhibits secretion of insulin, glucagon, and somatotropin
	PP cells	Pancreatic polypeptide	Inhibits secretion of pancreatic enzymes and HCO_3^-
Thyroid glands	Follicular cells	Thyroid hormones (T_3 and T_4)	Increase metabolic rate
	Parafollicular or C cells	Calcitonin	Lowers blood Ca^{2+} levels by inhibiting osteoclast activity
Parathyroid glands	Chief cells	Parathyroid hormone (PTH)	Raises blood Ca^{2+} levels by stimulating osteoclast activity
Pineal gland	Pinealocytes	Melatonin	Regulates circadian rhythms


پایگاه تکناز
Taknaz.ir

Photo: Khalil Gholami

Fars News Agency

Photo: Khalil Gholami

Fars News Agency