

**In the name of GOD**



**General Anatomy  
For  
Paramedicine Student**

**By  
Dr. Saeednia**

# Anatomical Terms



History

Methods Of Study

Anatomical Position

Anatomical Planes

Terms Related To Anatomical  
Position

Terms Related To Motion

# History



Anatomy

First time has been studied  
500 years BCC in Egypt

Function and structure of body

Geography of body

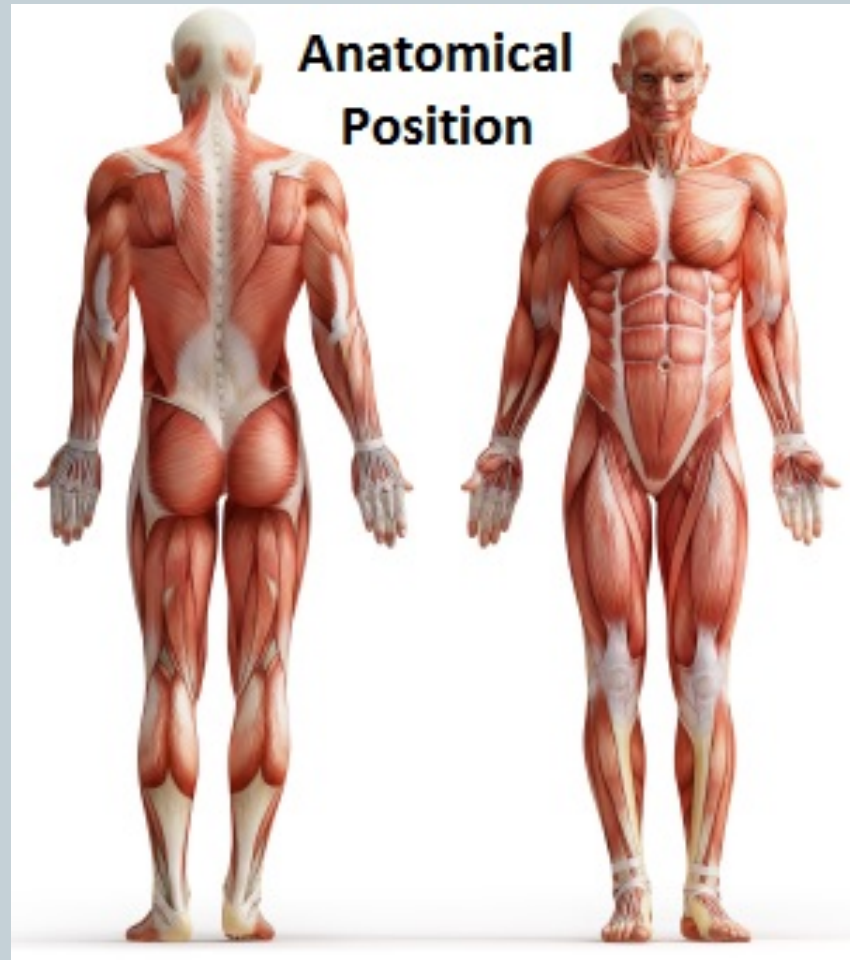
Ana= up / tomy= cut /  
cutting up

# Methods



- **Regional Anatomy**
  - Head & Neck
  - Trunk (Thorax, Abdomen, Pelvis)
  - Upper & Lower Limb
  
- **Systemic Anatomy**
  - Cardiovascular System
  - Digestive System

# Anatomical position



# Anatomical plan



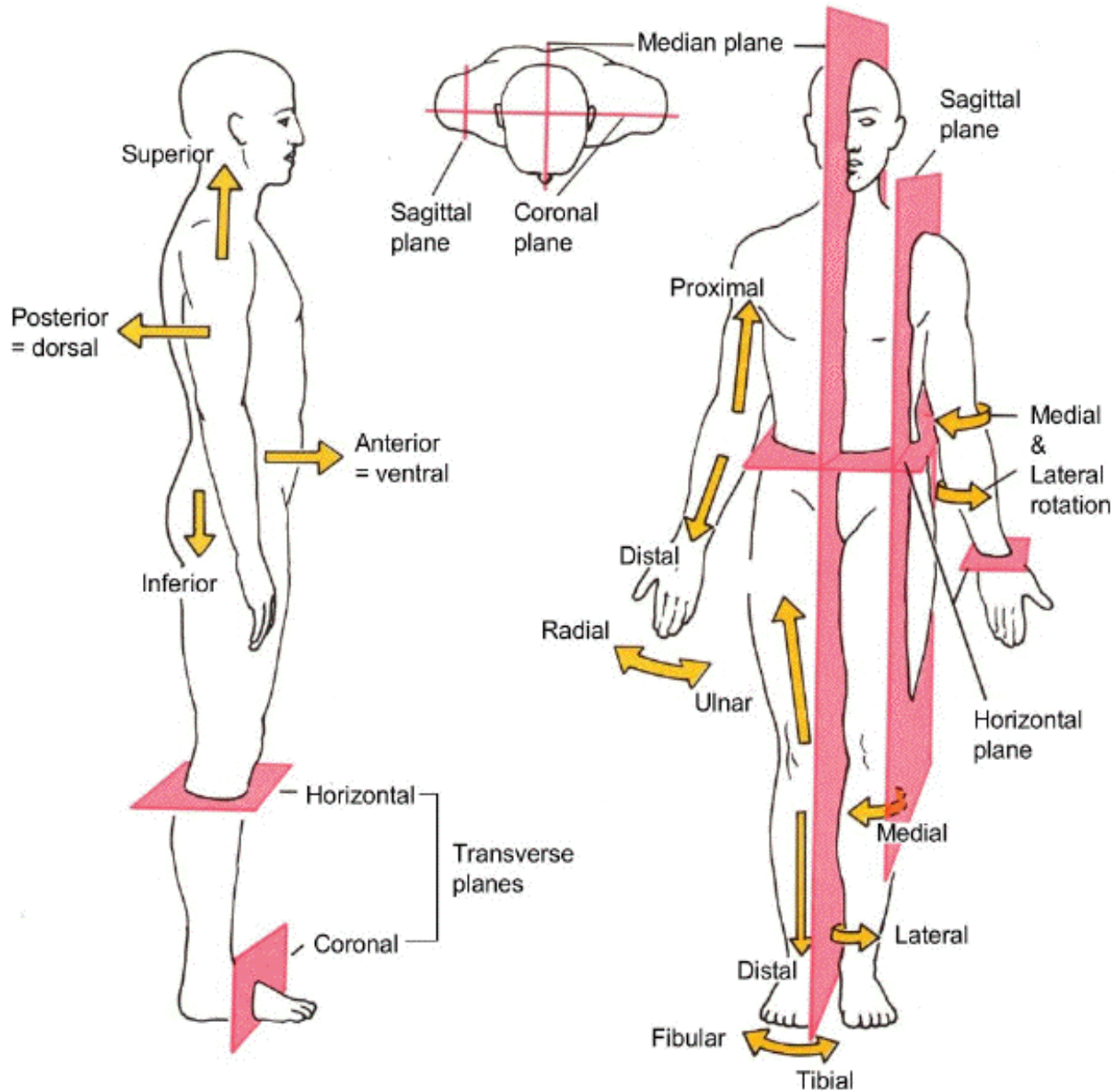
**Anatomical  
plane**

**Median  
plane**

**Sagittal  
planes**

**Coronal  
plane**

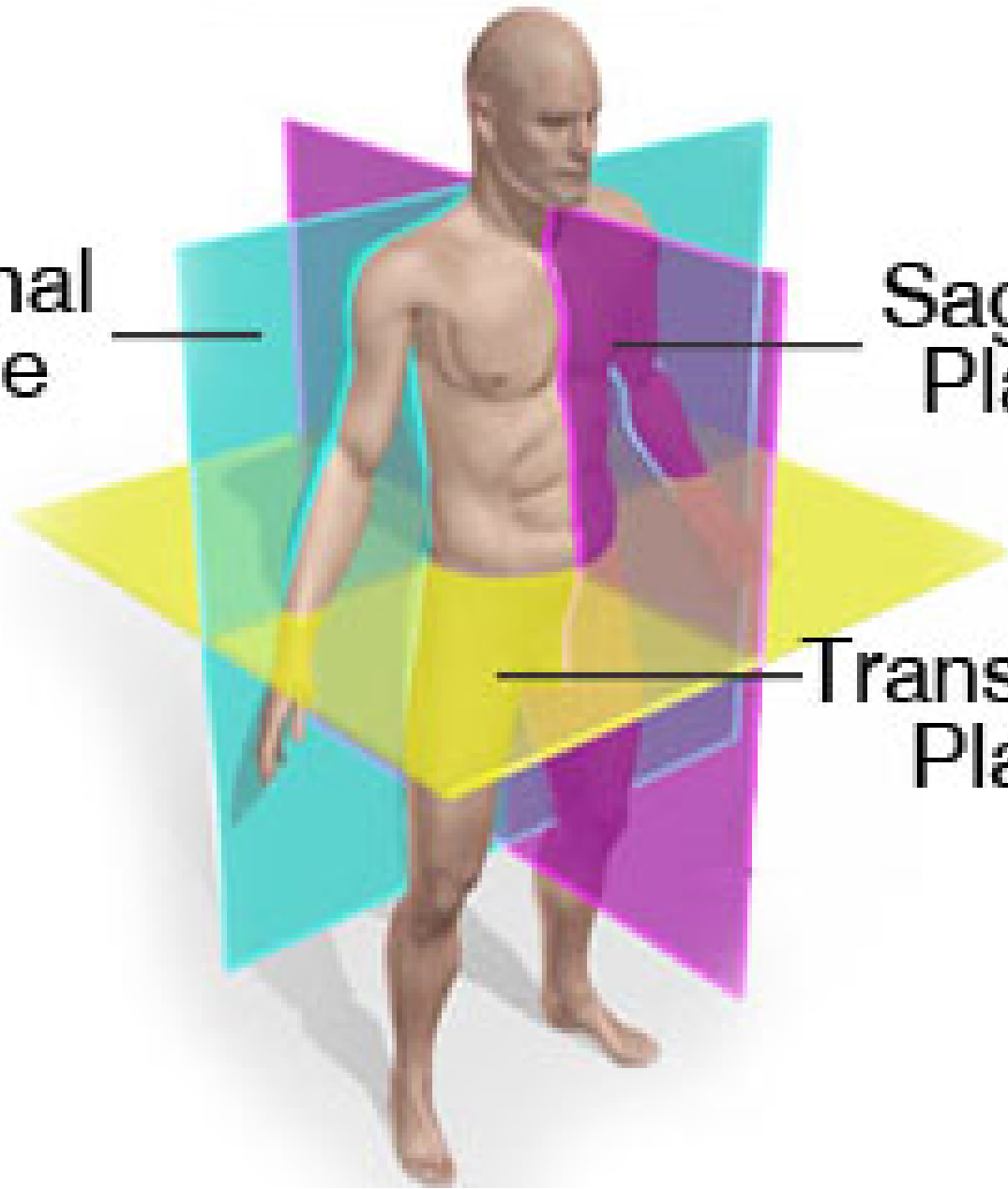
**Transverse  
planes**



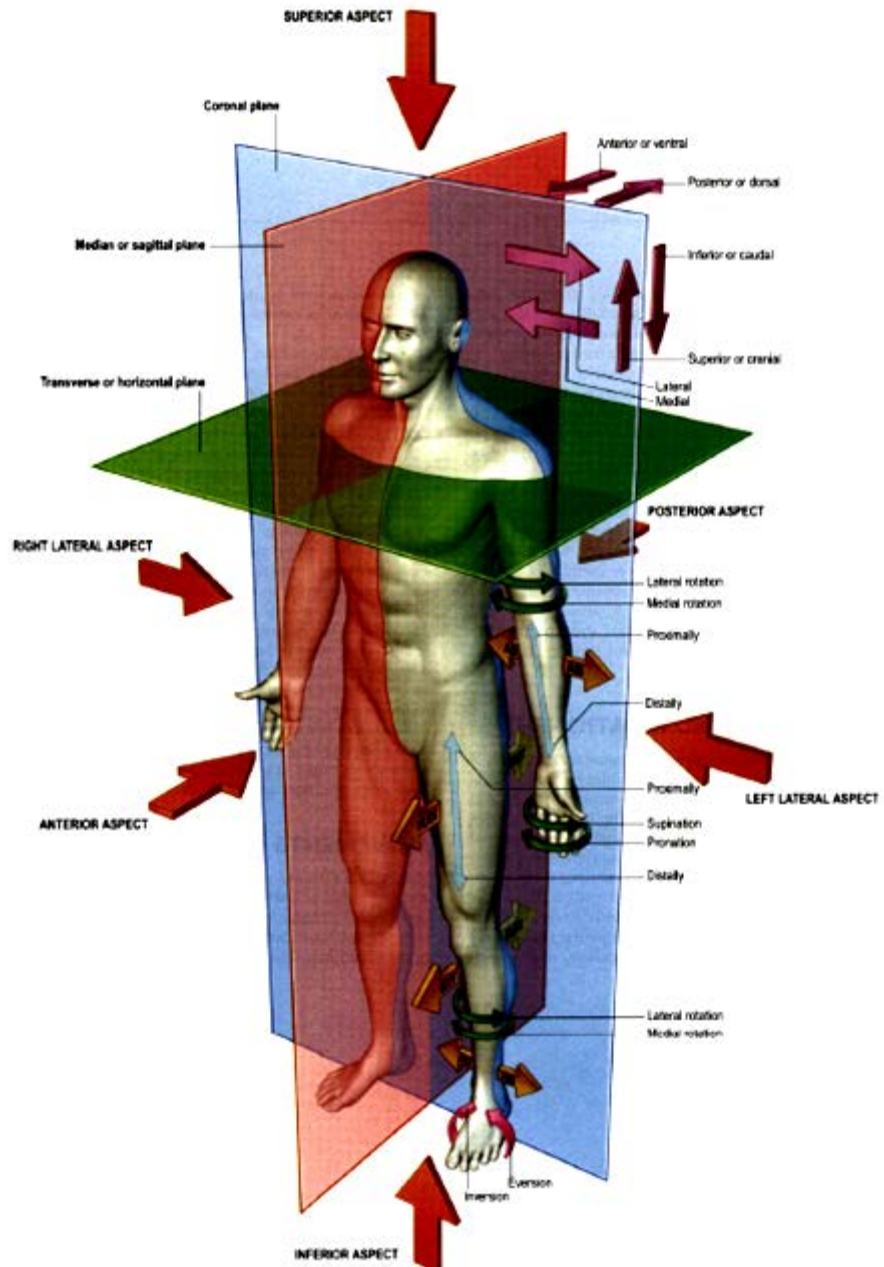
Coronal Plane

Sagittal Plane

Transverse Plane







# Terms Related To Anatomical Position



Anterior (Palmar / Plantar) / Posterior (Dorsal)

Medial / Lateral

Proximal/ Distal

Superficial / Deep

Superior / Inferior

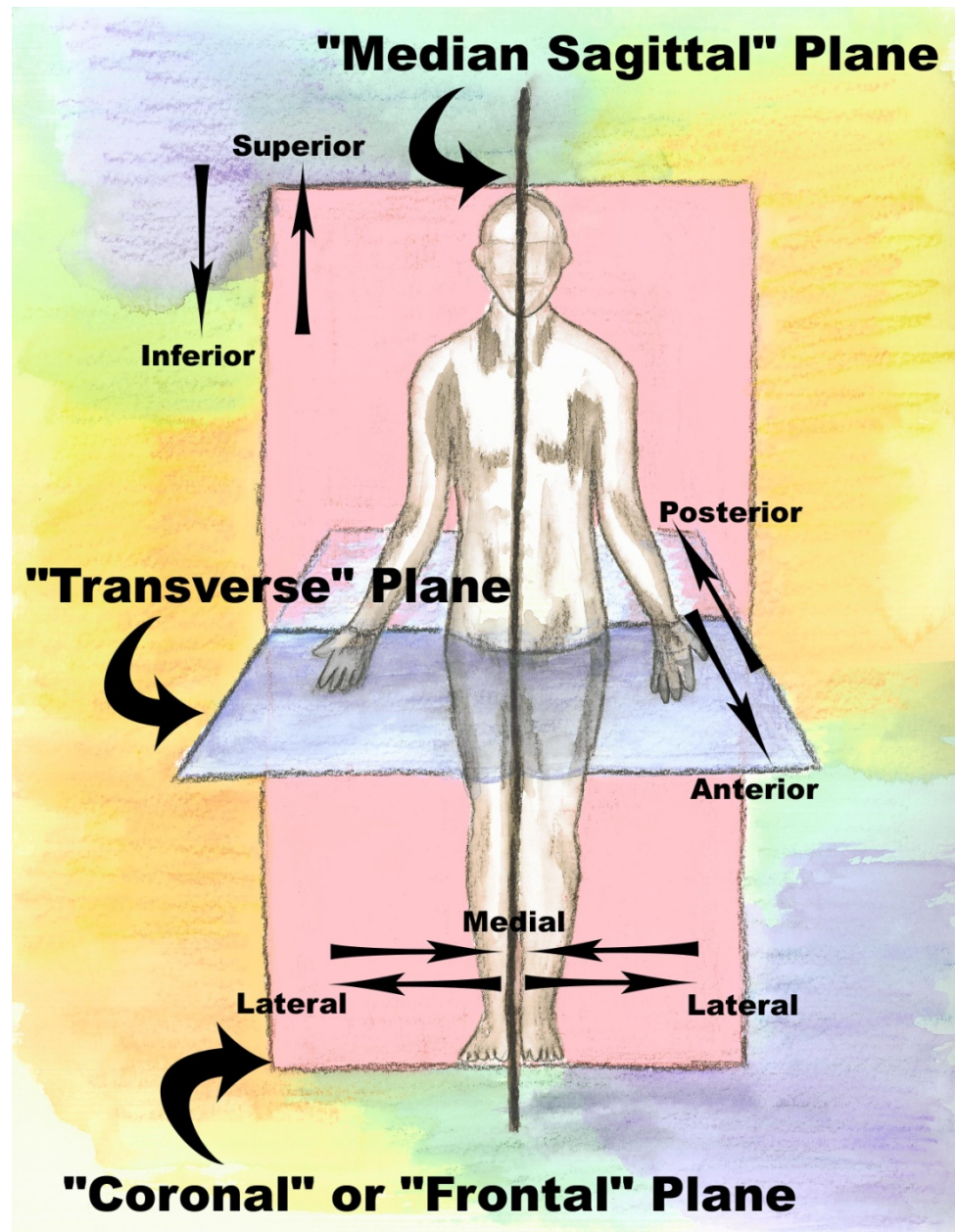
Internal / External

Ipsilateral / Contra Lateral

Unilateral / Bilateral

Cranial / Caudal

Supine / Prone

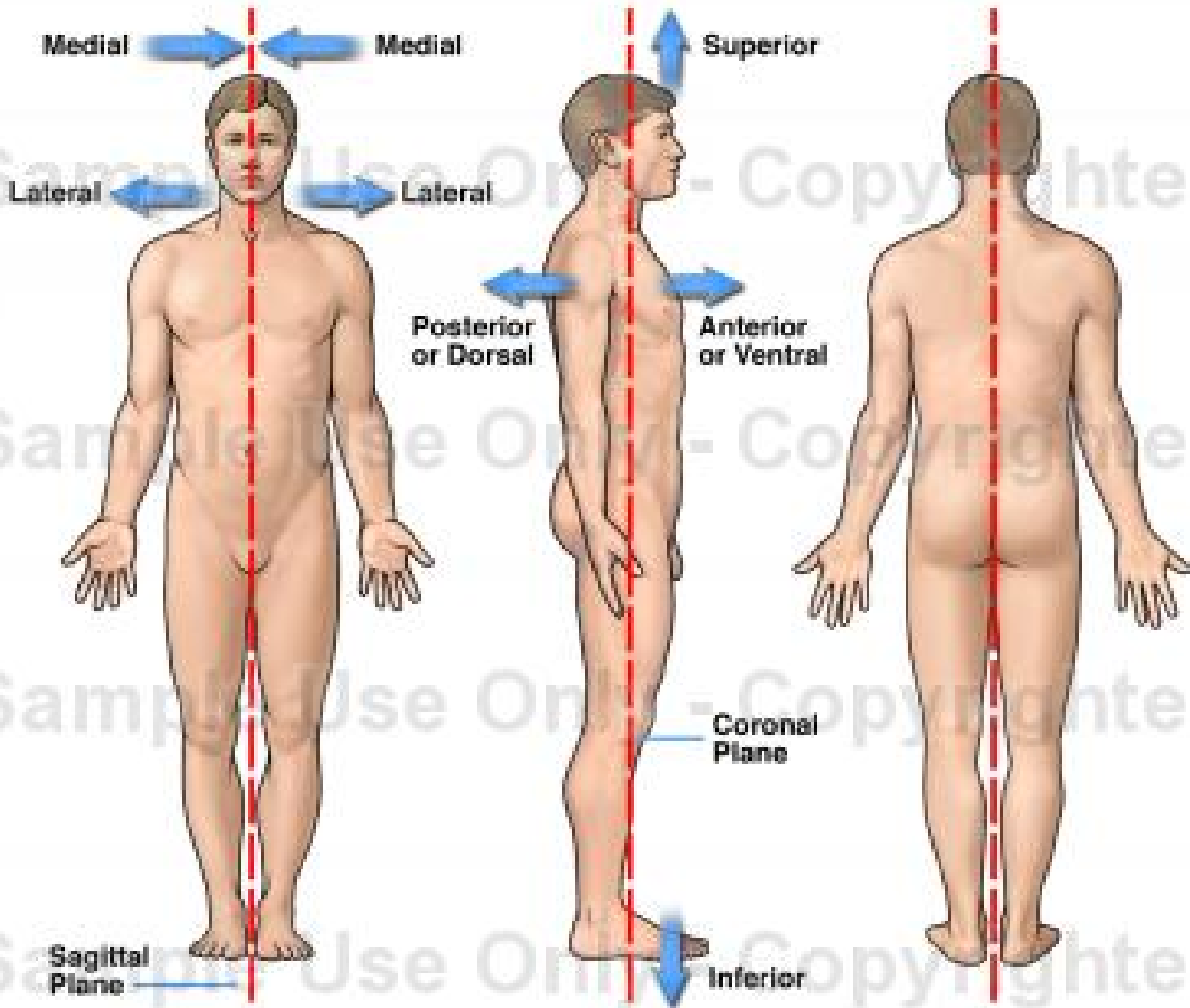


Sample Use Only - Copyrighted

**Anterior  
or Ventral View**

**Lateral  
or Side View**

**Posterior  
or Dorsal View**



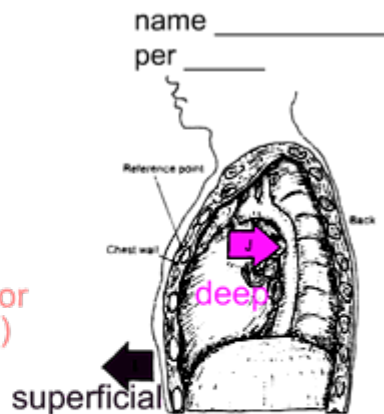
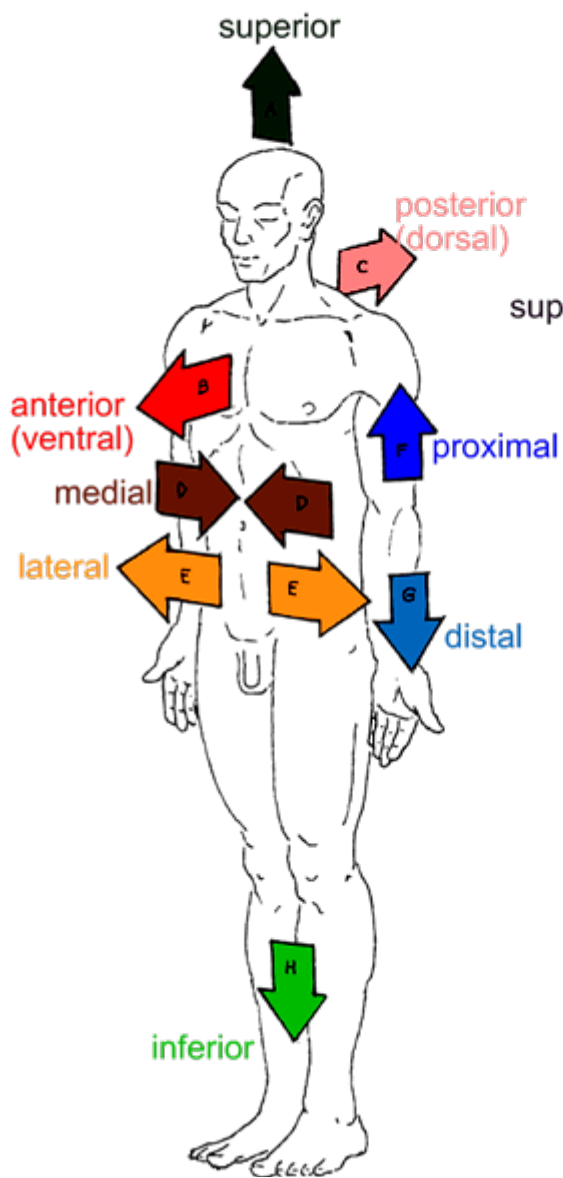
Sample Use Only - Copyrighted

Sample Use Only - Copyrighted

Sample Use Only - Copyrighted

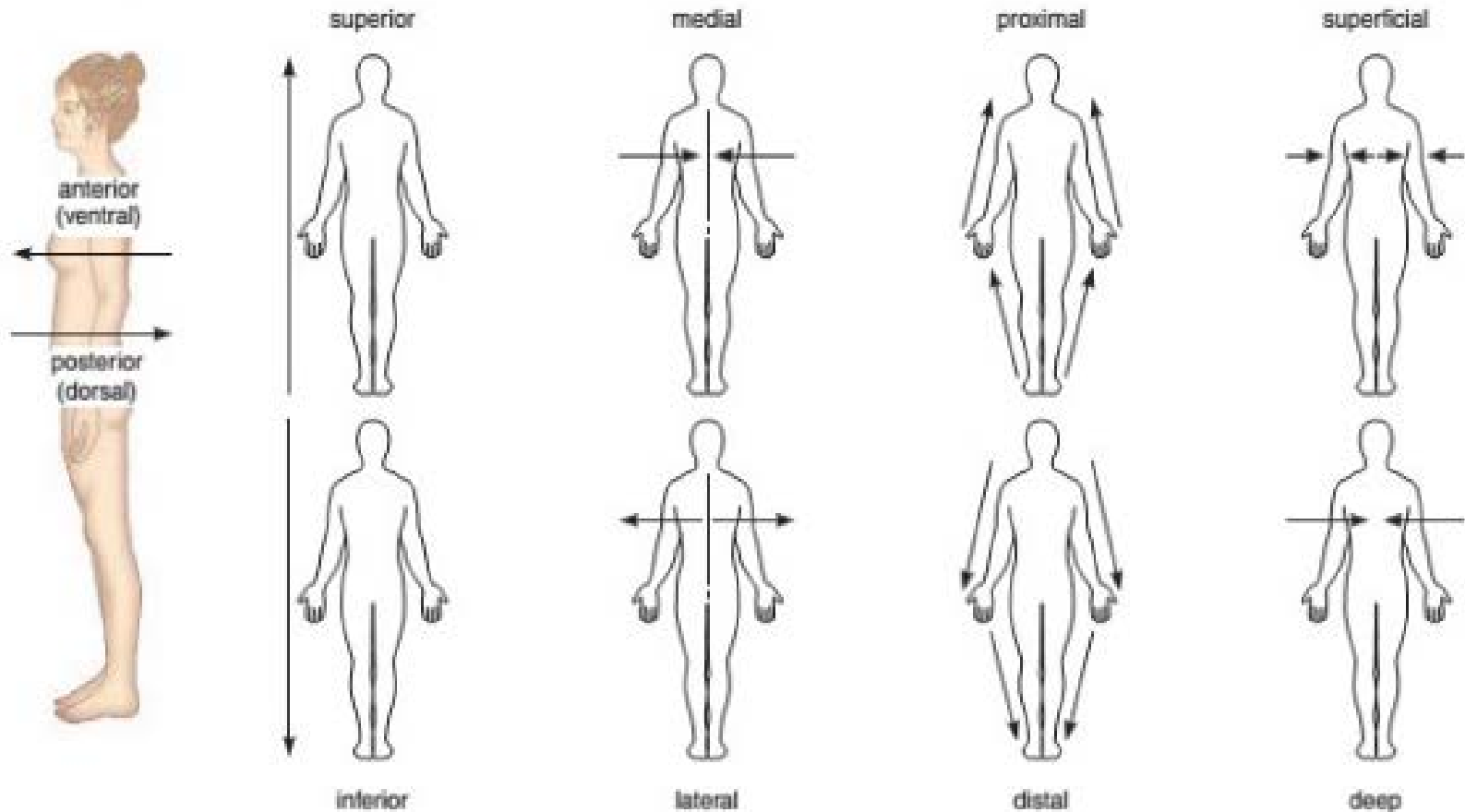
Sample Use Only - Copyrighted

**title: Anatomical position and directional terminology**



# Directional terms.

Directional terms tell us where body parts are located with reference to the body in anatomical position.



# Terms Related To Motion



Flexion ( Dorsal F, Plantar F, Lateral F ) / Extension

Abduction / Adduction

Rotation ( Medial , Lateral )

Circumduction

Apposition

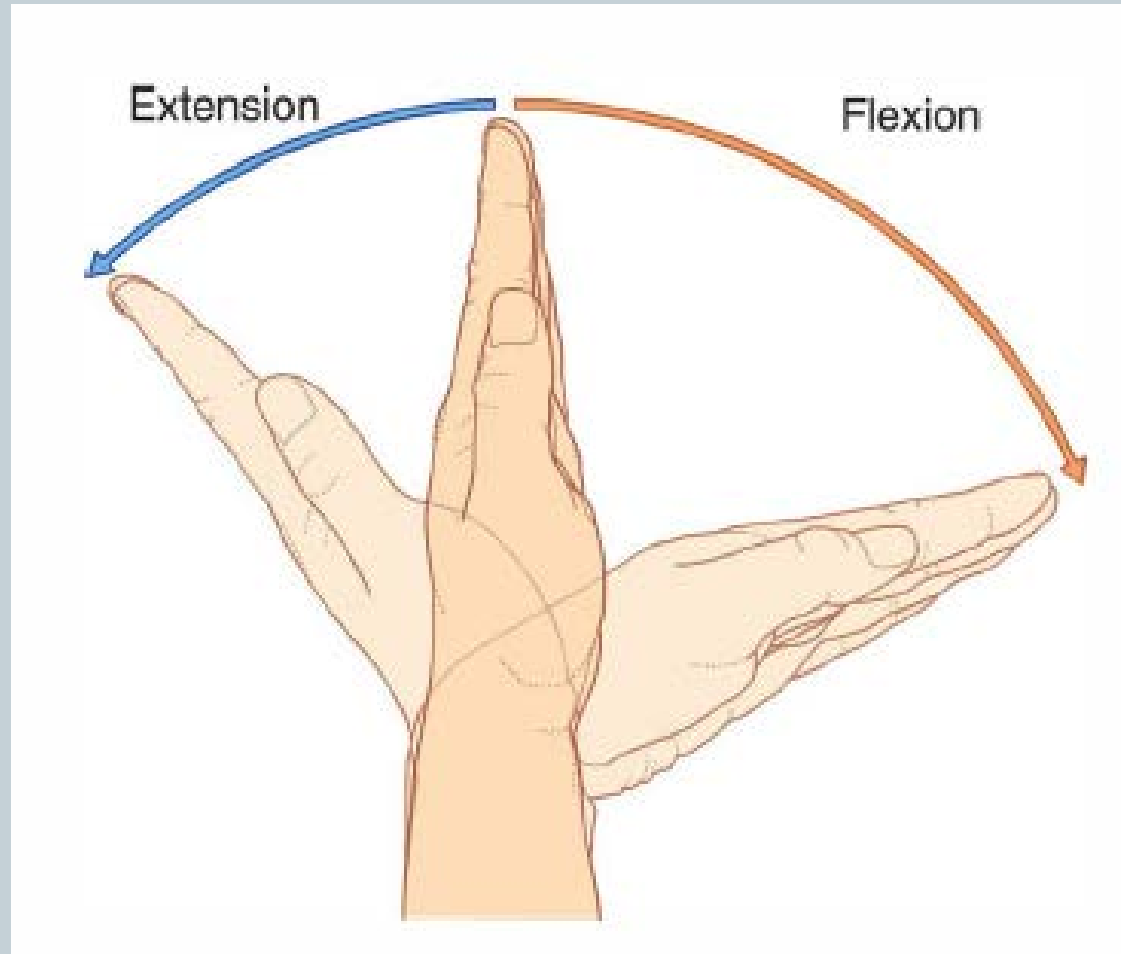
Protrusion / Retrusion

Depression / Elevation

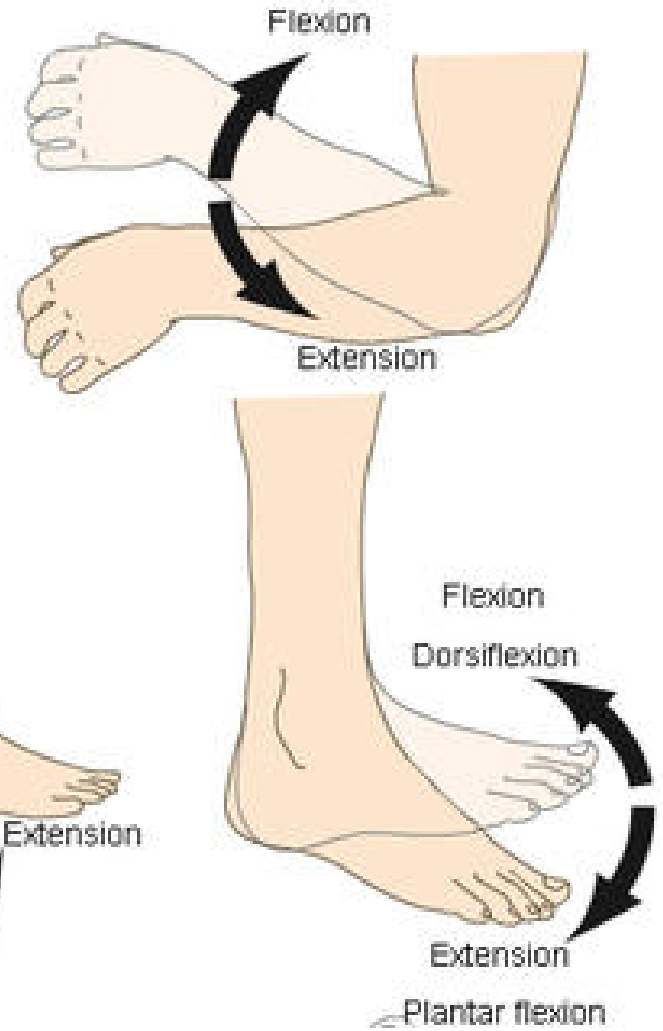
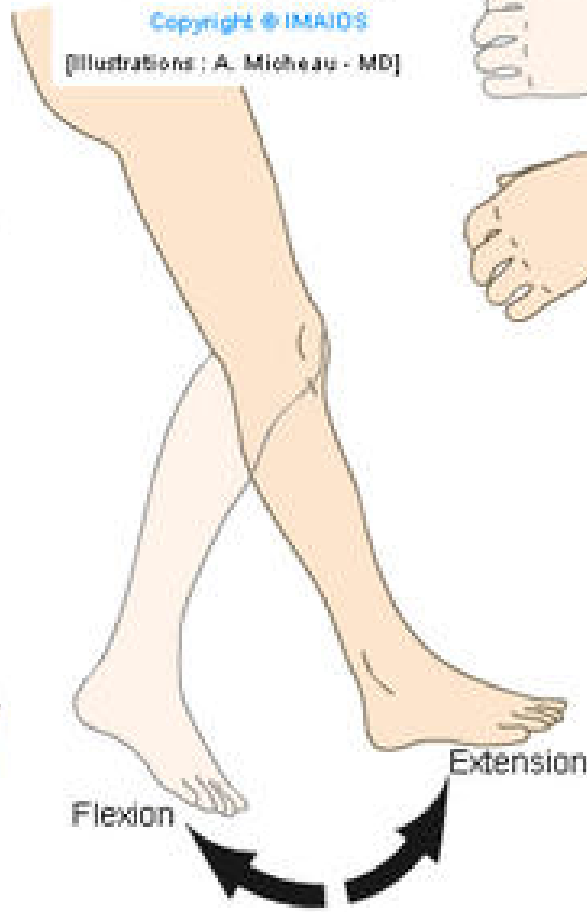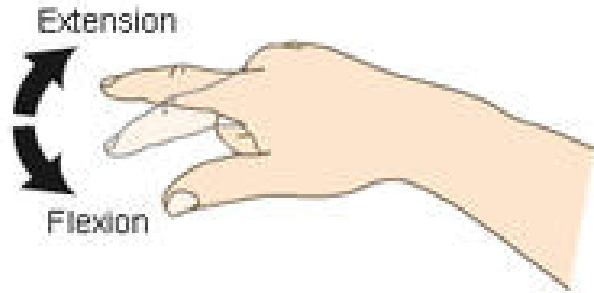
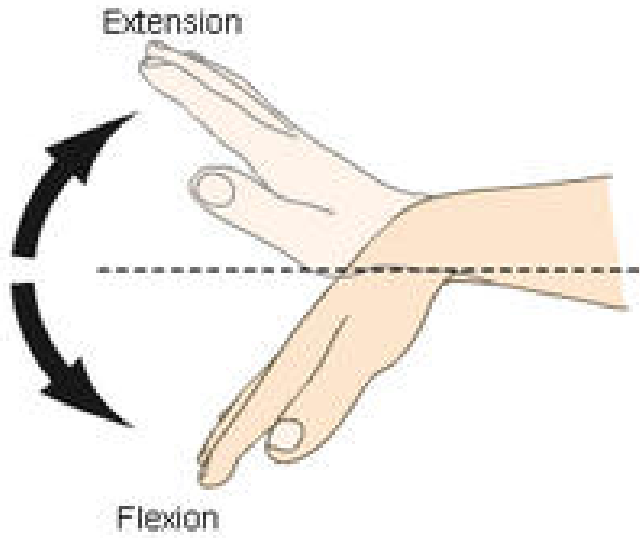
Inversion / Eversion

Supination / Pronation

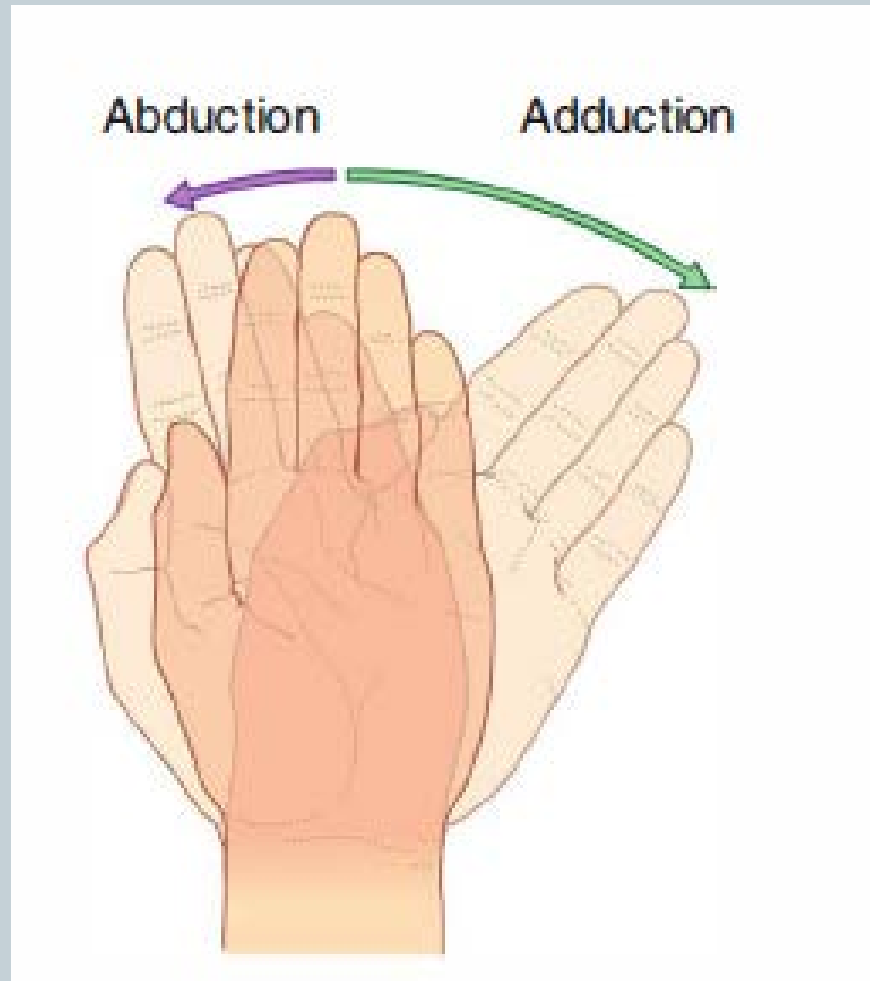
# Flexion / extension

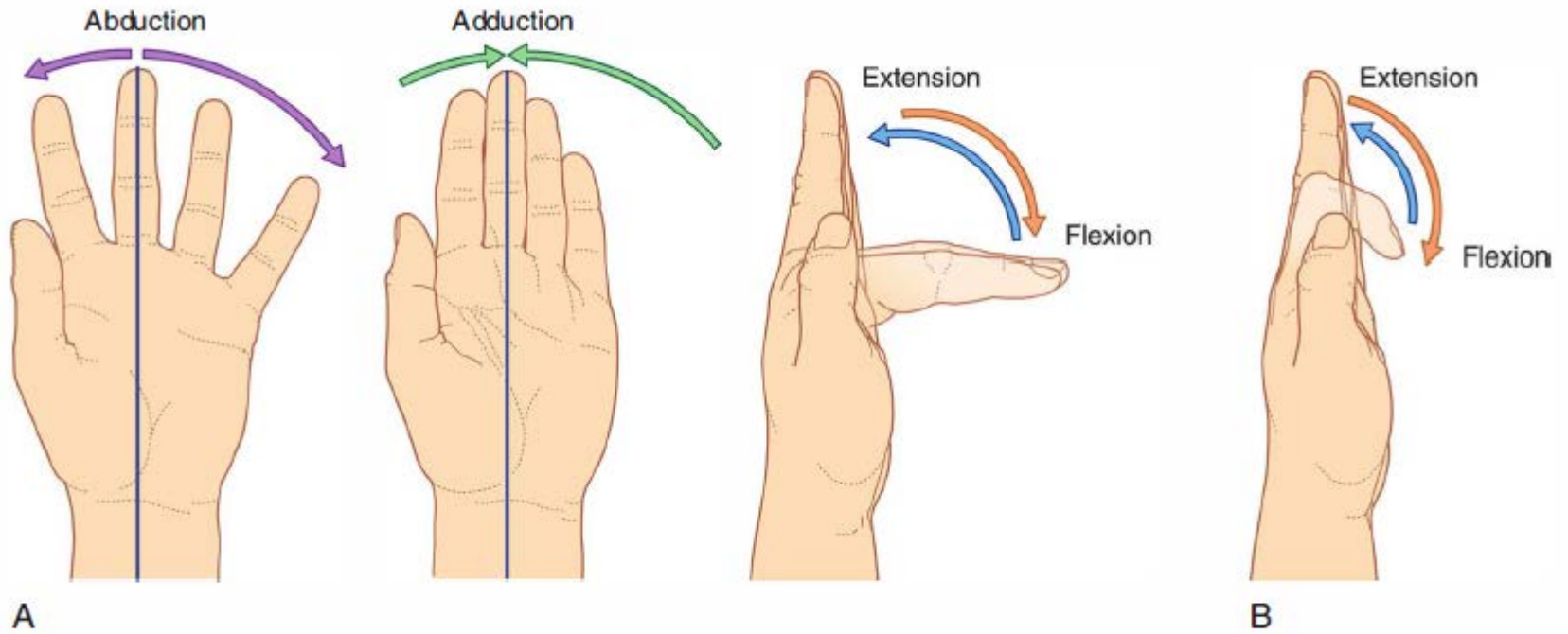






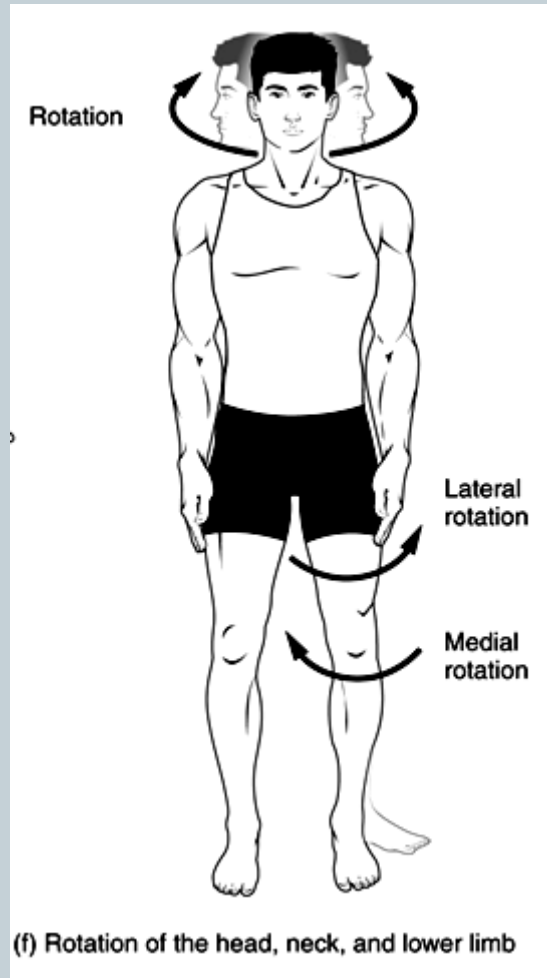
# Adduction / abduction



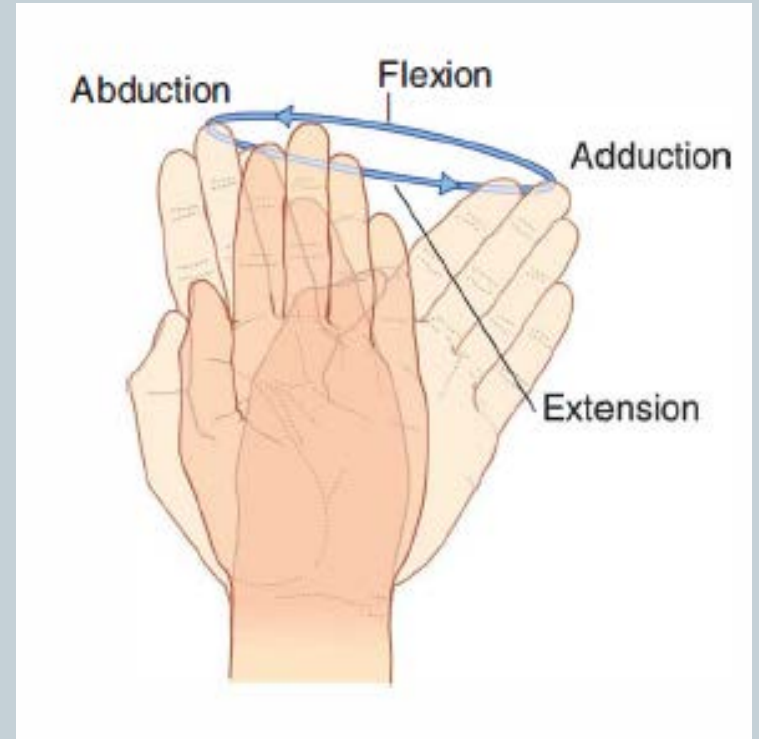
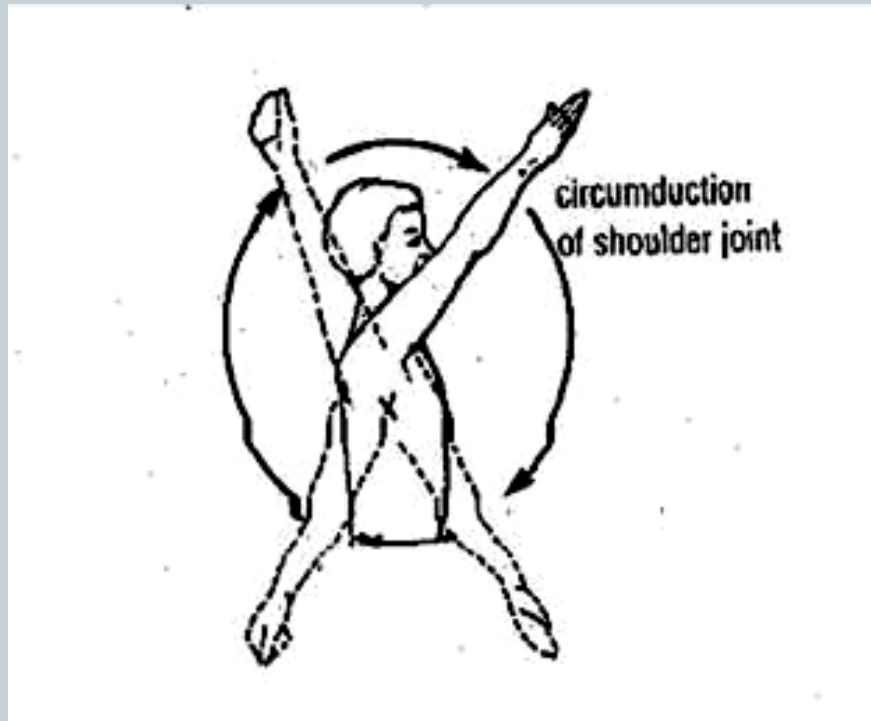


**Fig. 7.8** Movements of the metacarpophalangeal (A) and interphalangeal (B) joints.

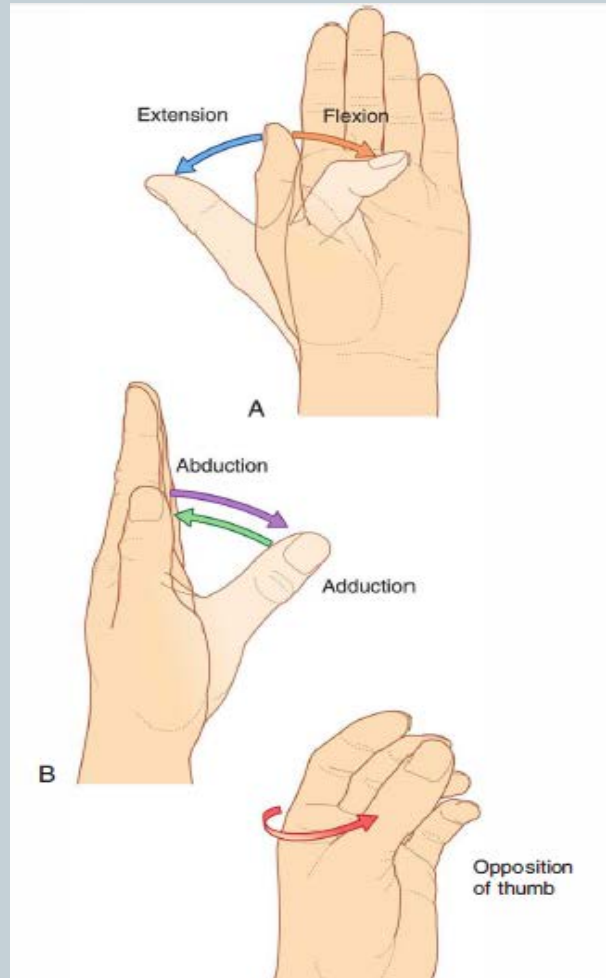
# Medial & lateral rotation



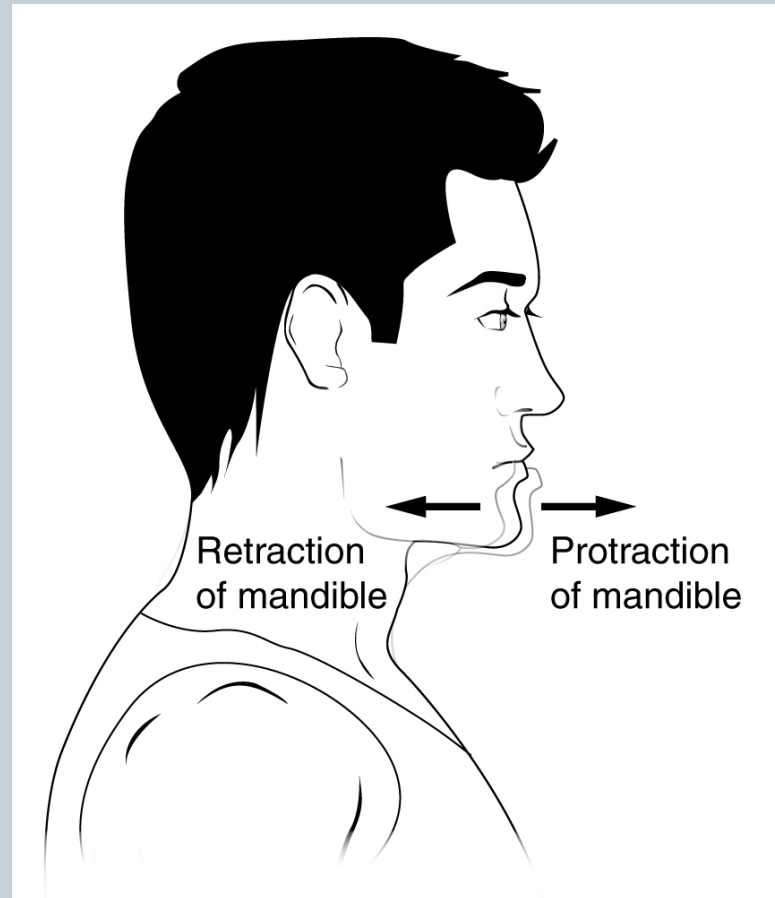
# Circumduction



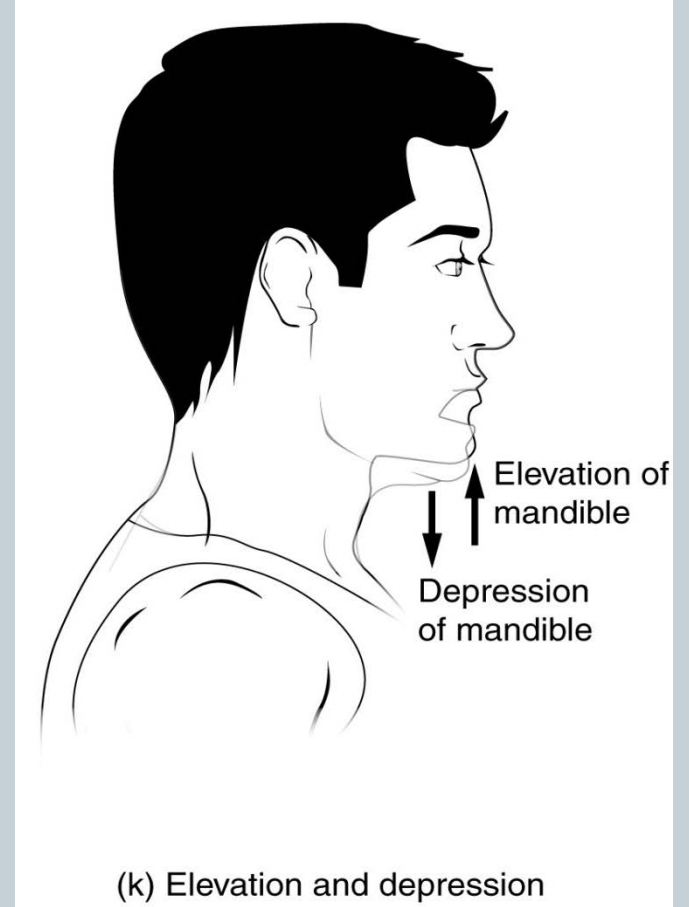

# Apposition



# Protrusion / Retrusion

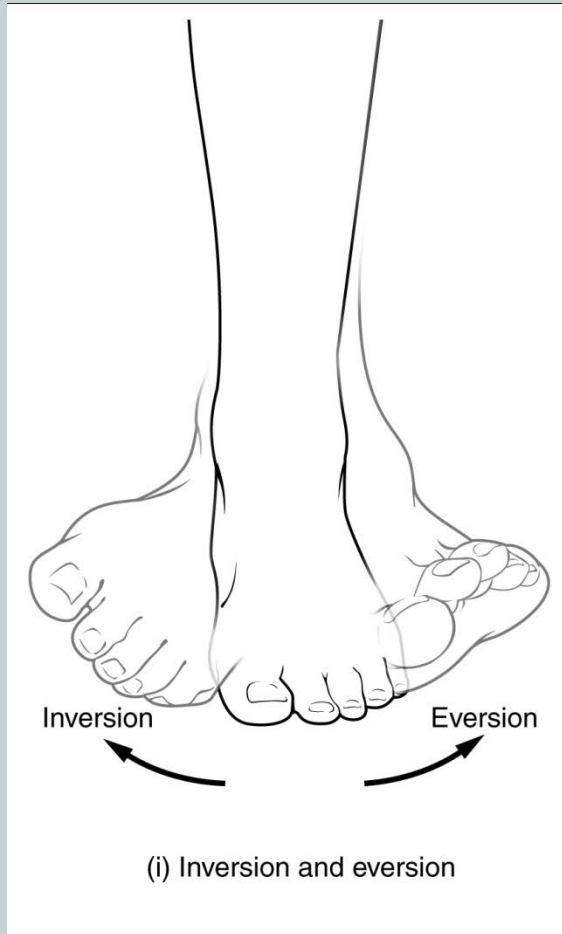


# Depression / Elevation

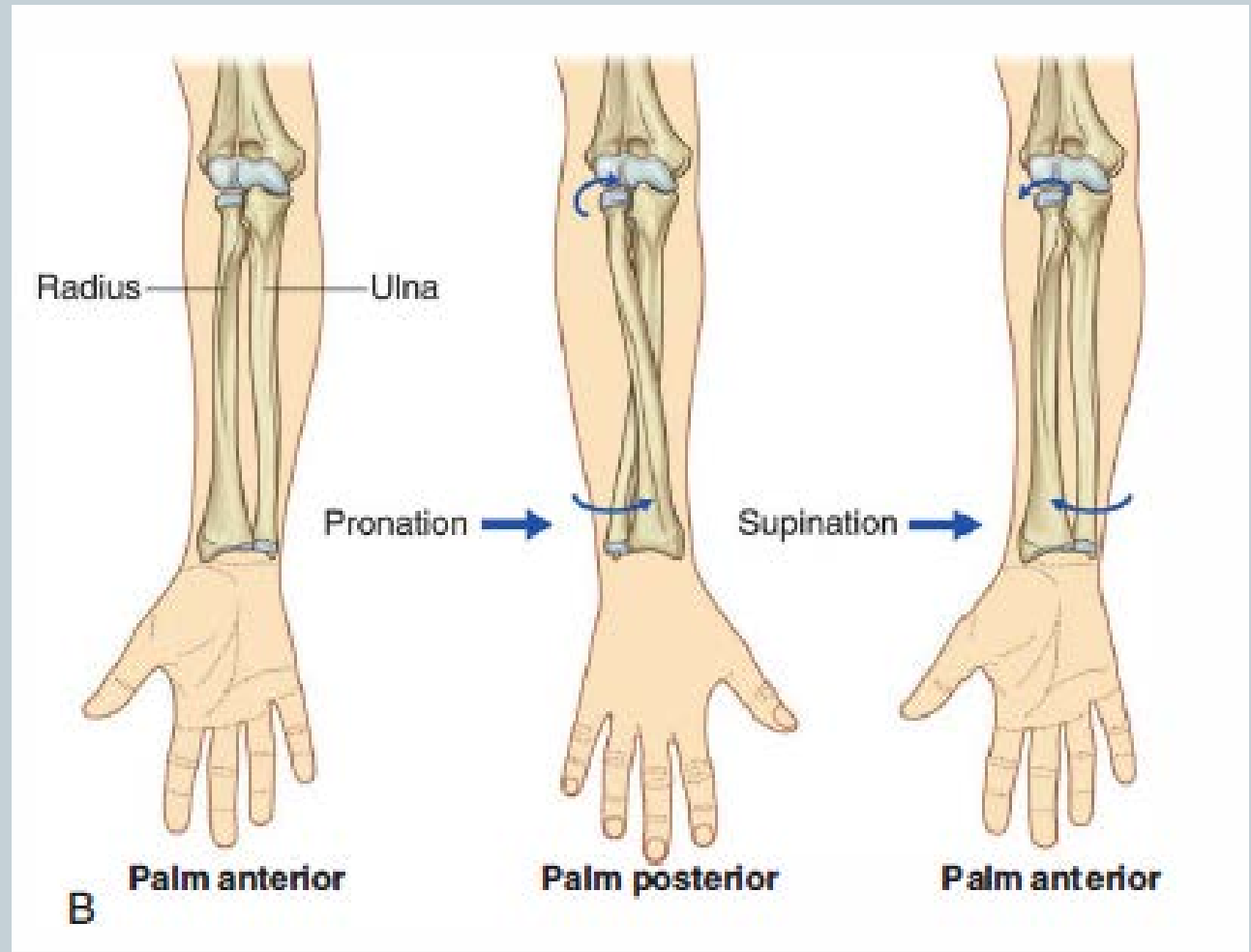
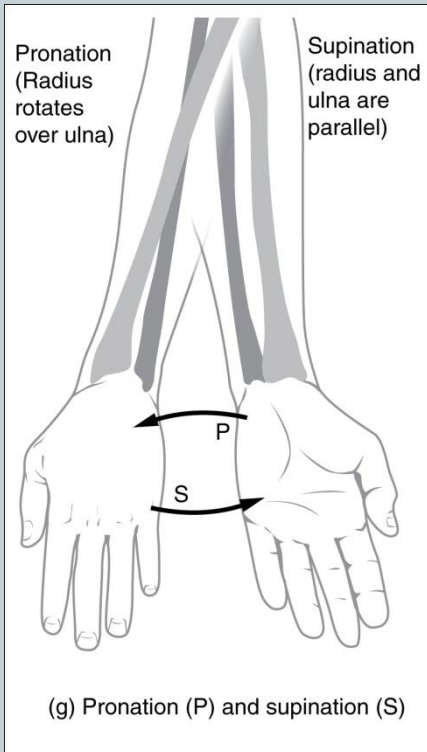


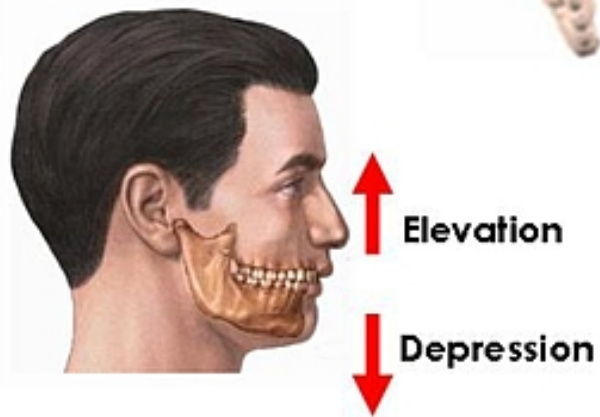
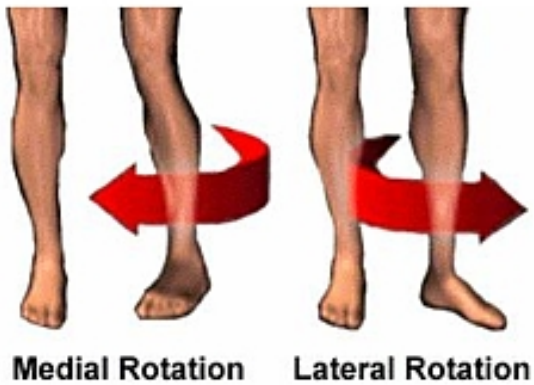
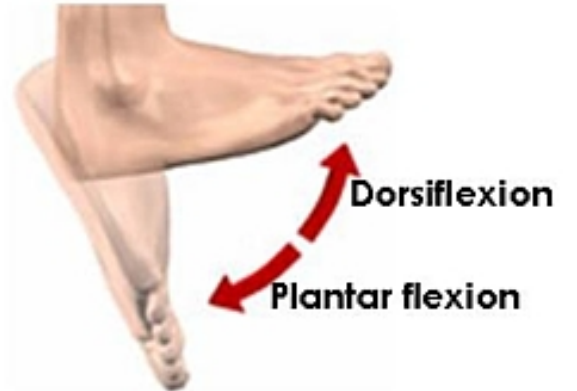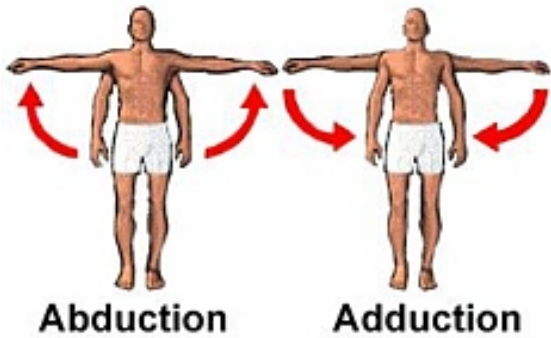
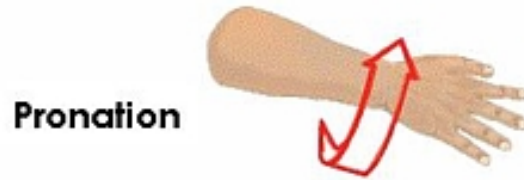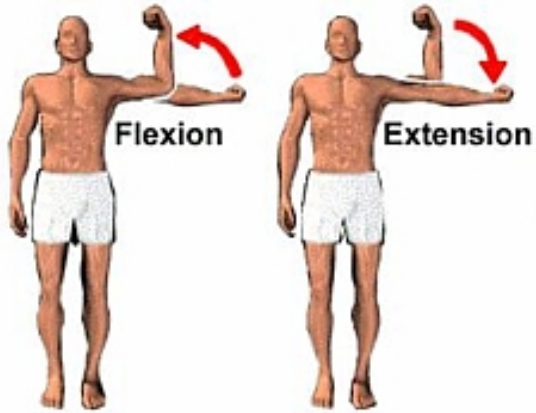


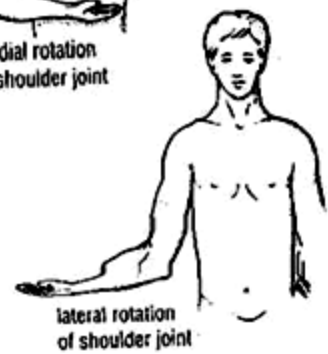
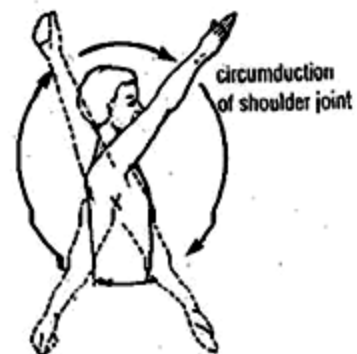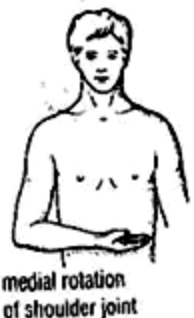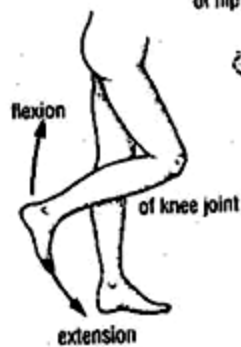
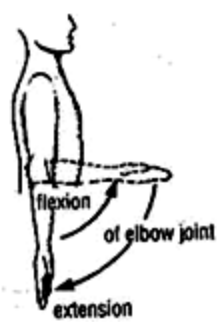
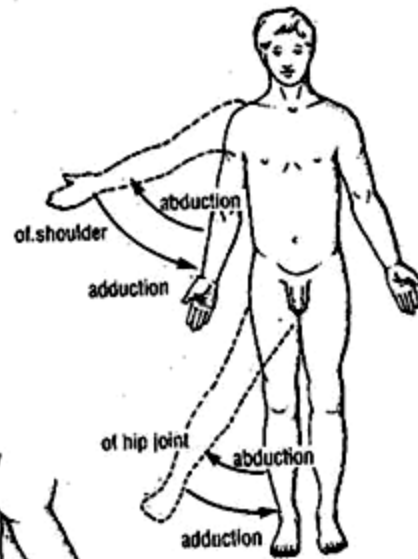
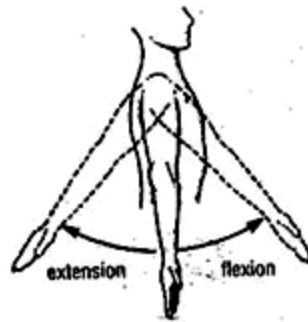
# Inversion / Eversion

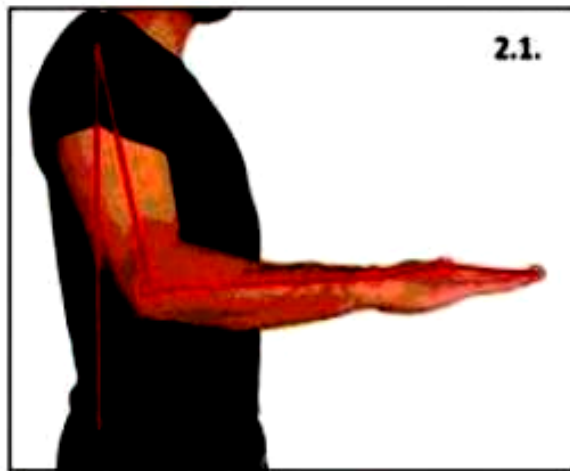


# Pronation / supination



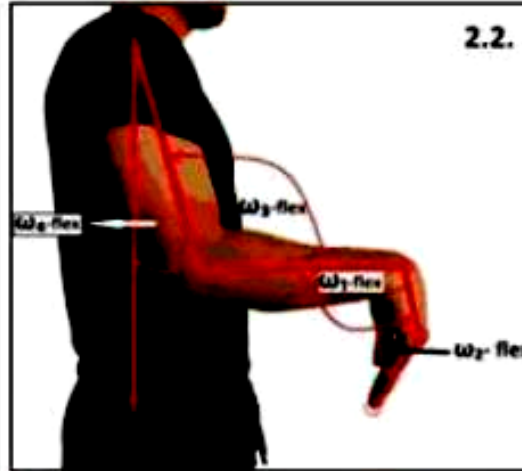






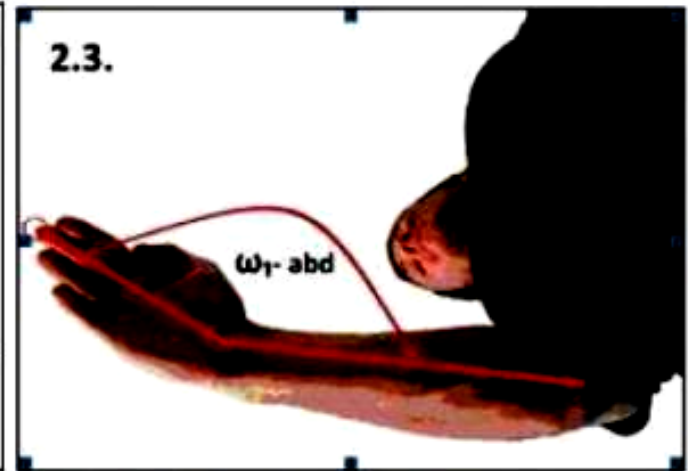
2.1.

Fig. 2.1. Starting position



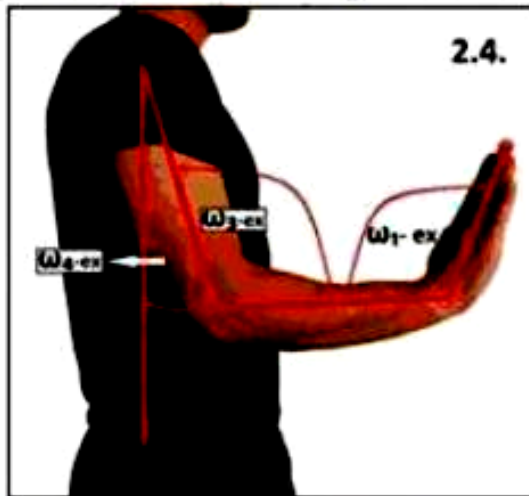
2.2.

Fig. 2.2. Phase 1 – wrist flexion



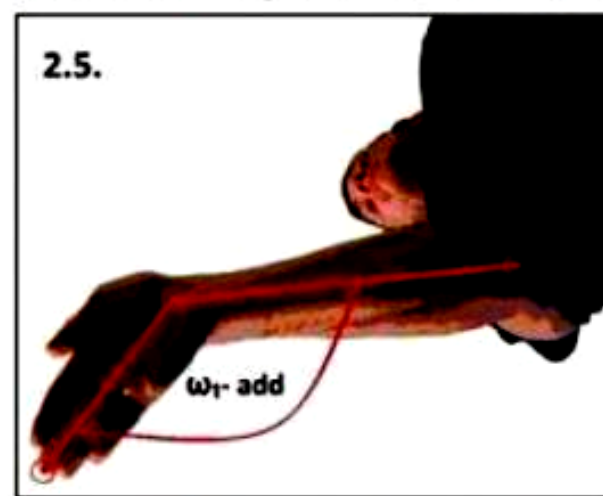
2.3.

Fig. 2.3. Phase 2 – wrist abduction



2.4.

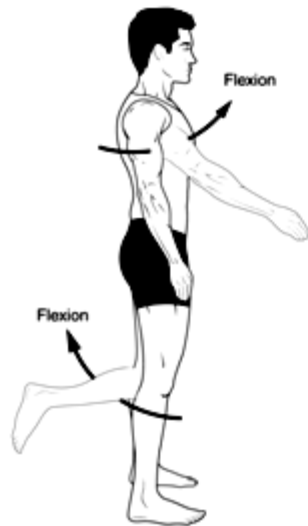
Fig. 2.4. Phase 3 – wrist extension



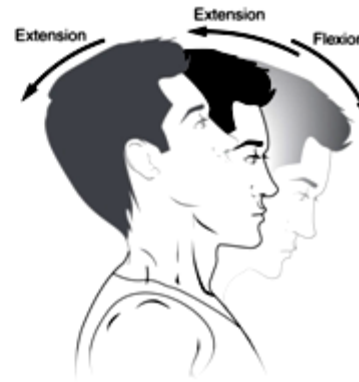
2.5.

Fig. 2.5. Phase 4 – wrist adduction

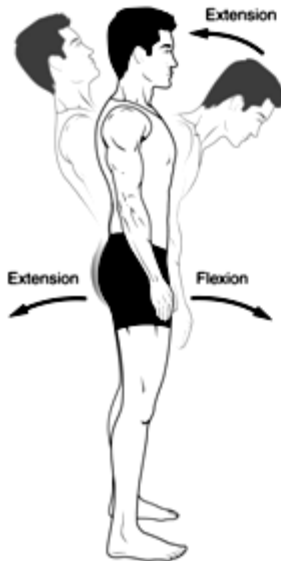
**Figure 2.** Goniometric analysis of image frames showing maximum angles of flexion (Fig.2.2.), abduction (Fig.2.3.), extension (Fig. 2.4.) and adduction (Fig. 2.5.) of the wrist joint during dynamic SCE-w exercise



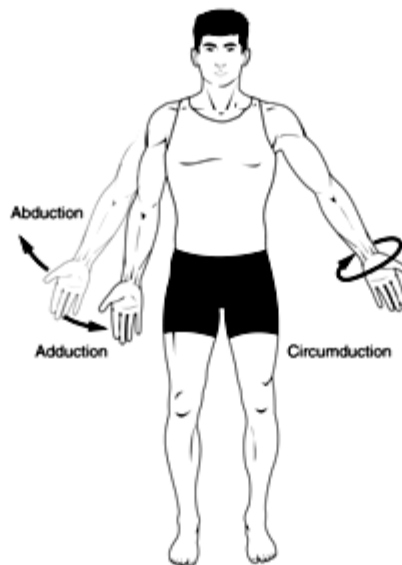
(a) and (b) Angular movements: flexion and extension at the shoulder and knees



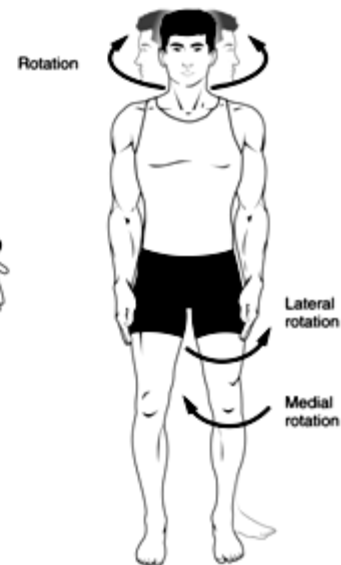
(c) Angular movements: flexion and extension of the neck



(d) Angular movements: flexion and extension of the vertebral column



(e) Angular movements: abduction, adduction, and circumduction of the upper limb at the shoulder



(f) Rotation of the head, neck, and lower limb

